

Practice Advisor

# Clinical Casebook UltraPulse® Treatments

Worldwide collection of before and after images



PB-1003880 Rev. C

# Practice Advisor UltraPulse® Treatments

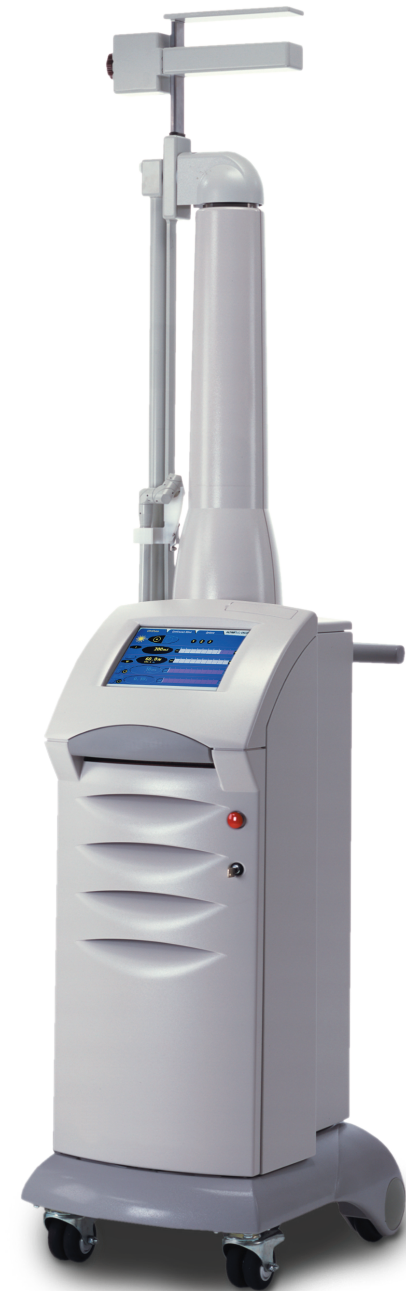## Images of typical treatment results, with the UltraPulse system

Indications depicted include:

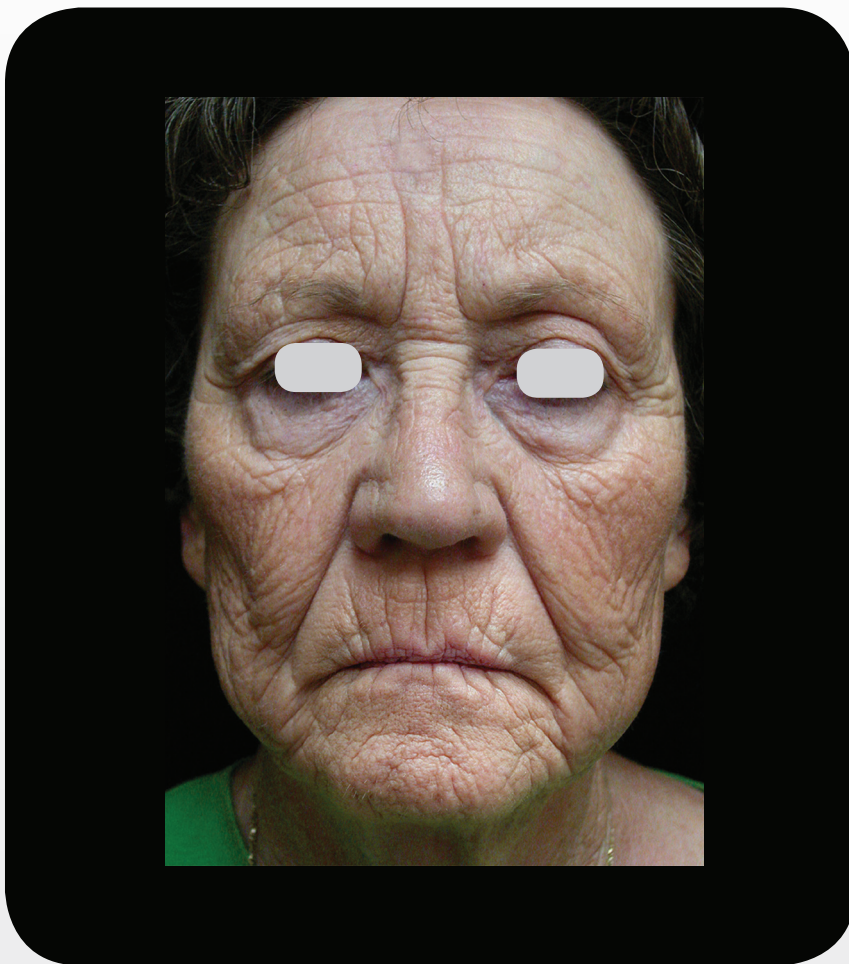
- Surgical scars
- Fractional ablative resurfacing
- Deep wrinkles
- Blepharoplasty
- Skin tags
- Syringomas
- Rhinophyma
- Dyschromia

### Warnings and risks

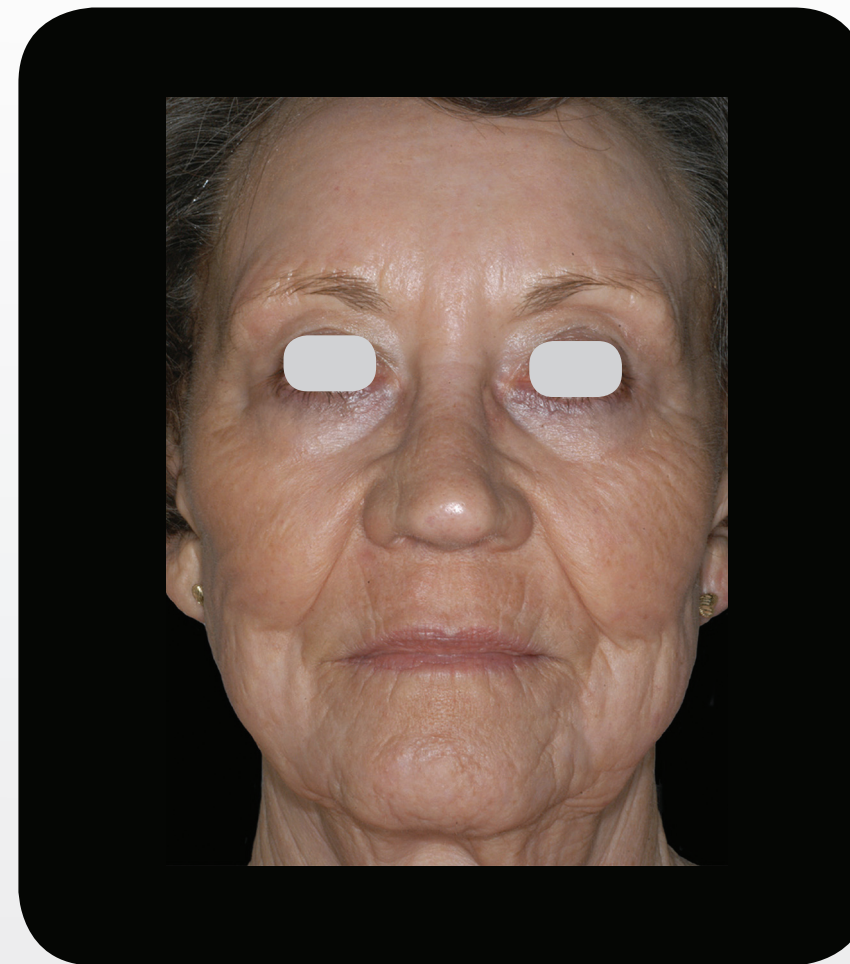
Lumenis CO<sub>2</sub> laser procedures are not suitable for everyone, for example patients who have taken Accutane (Isotretinoin) within the past 6-12 months, or had a history of keloid formation. Risks may include change of pigmentation, infection, redness or textural changes. Be sure to consult your physician regarding treatment options available and related contraindications and risks based on your individual concerns and medical history, before choosing a treatment.



# Deep Skin Resurfacing



Baseline

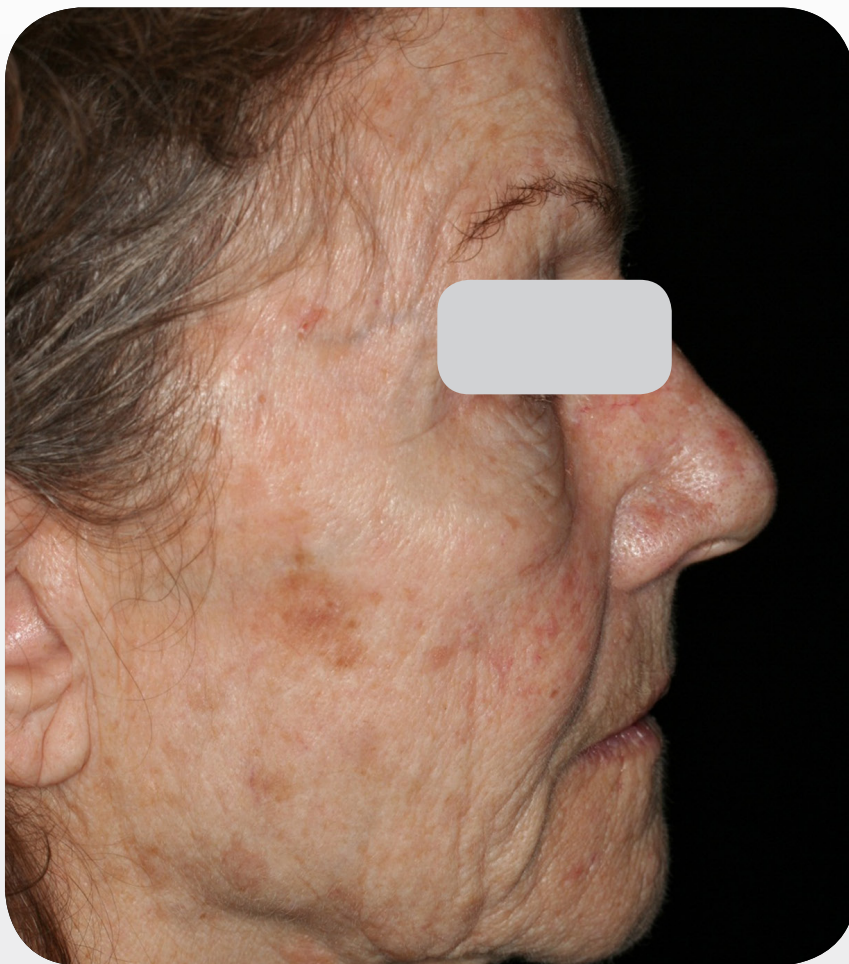

1 year after treatment

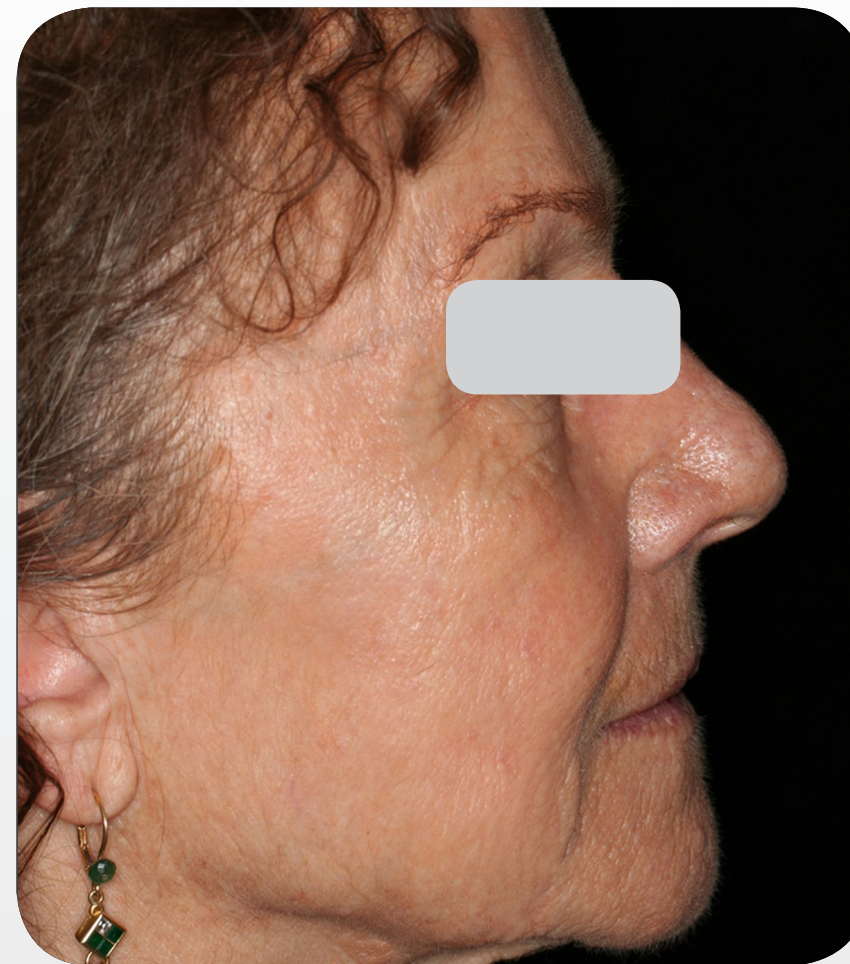Courtesy of Suzanne L. Kilmer, MD

PB-1003880 Rev C

# Deep Skin Resurfacing



Baseline

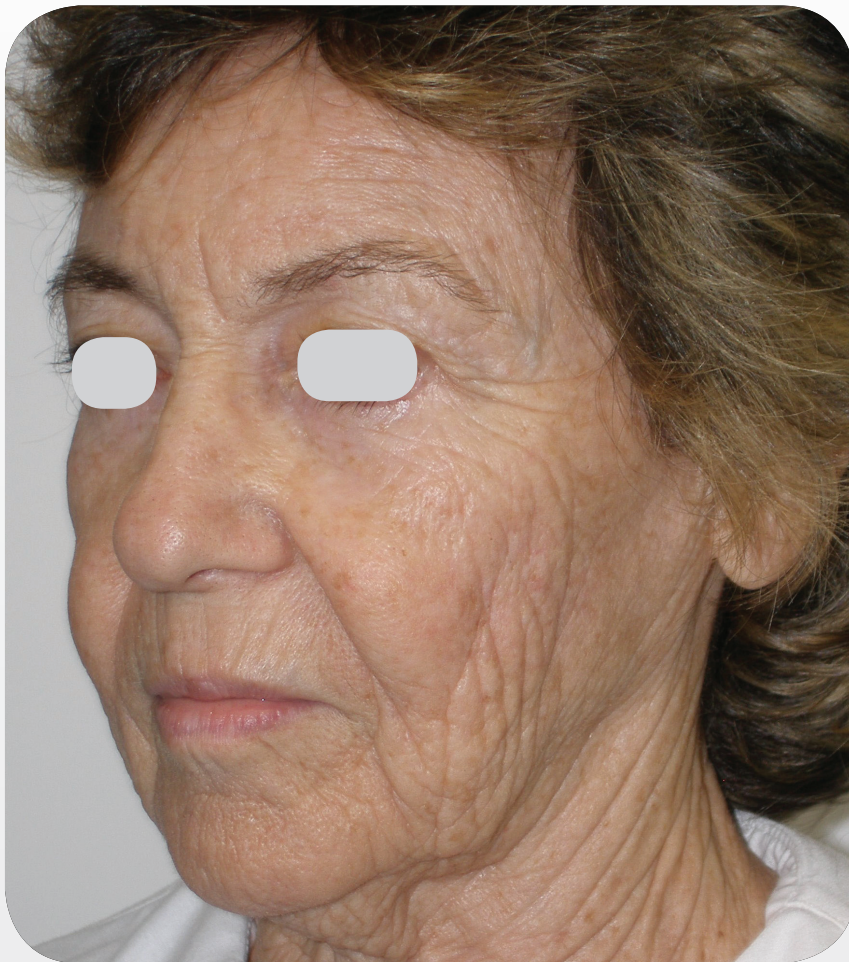


2 years after treatment

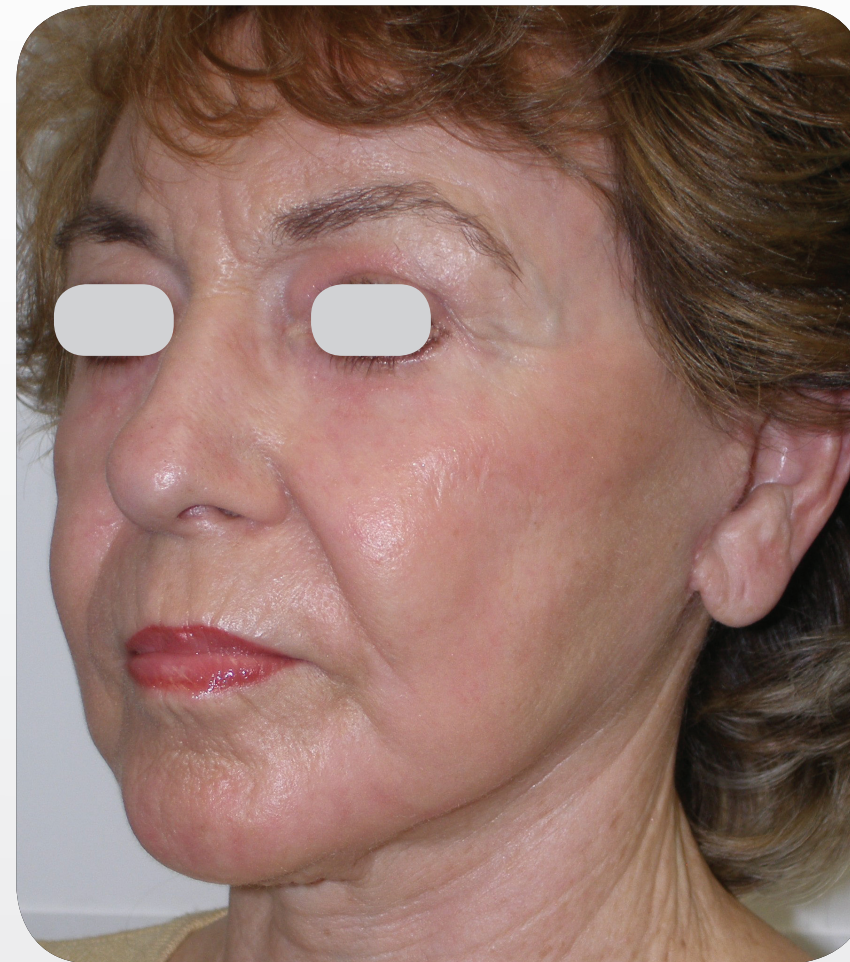
Courtesy of Matteo Tretti Clementoni, MD

PB-1003880 Rev C

# Deep Skin Resurfacing



Baseline

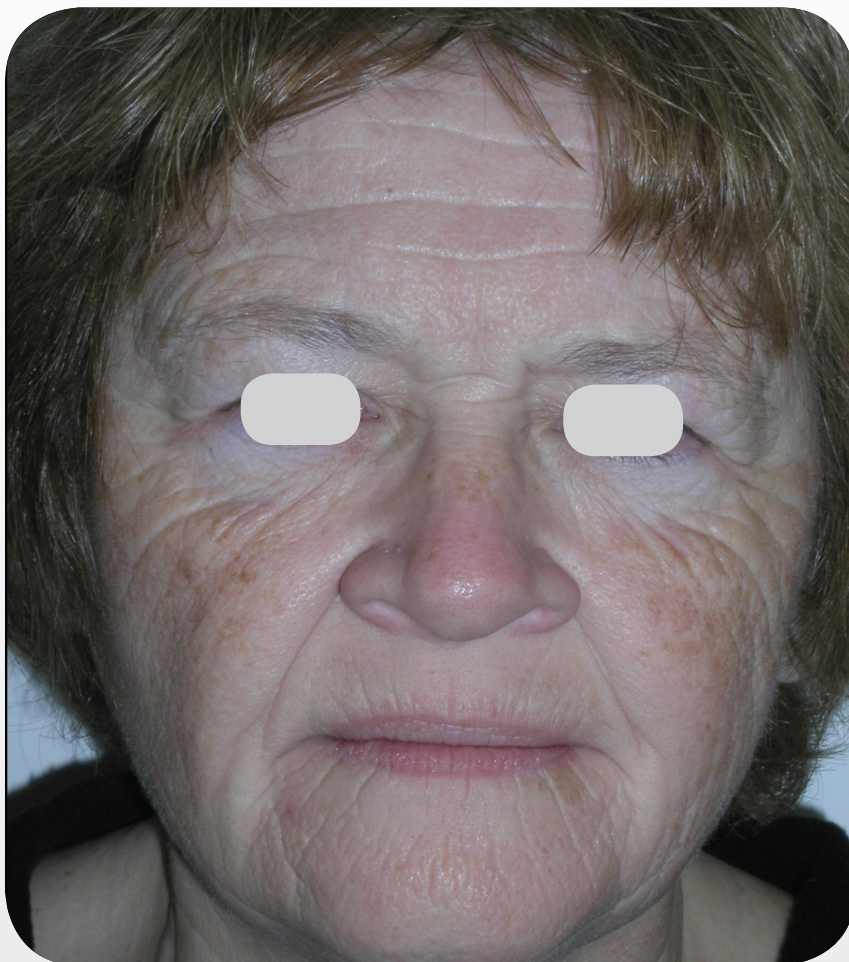


After treatment

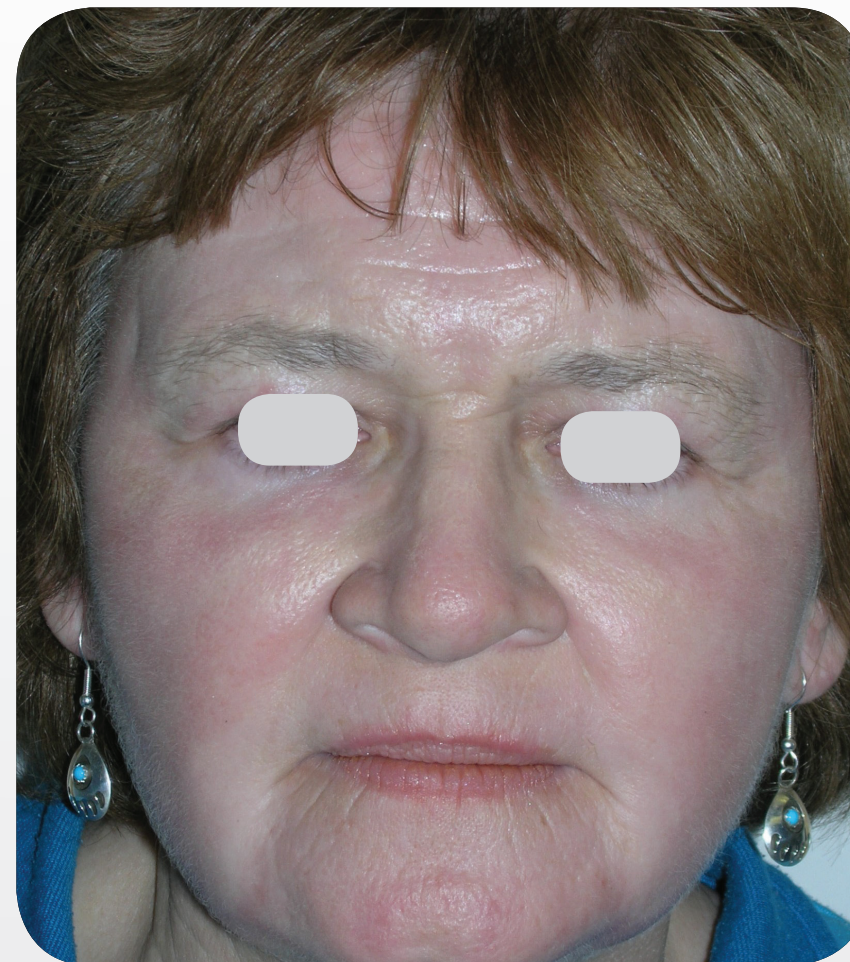
Courtesy of Joseph Niamtu III, DMD

PB-1003880 Rev C

# Deep Skin Resurfacing



Baseline

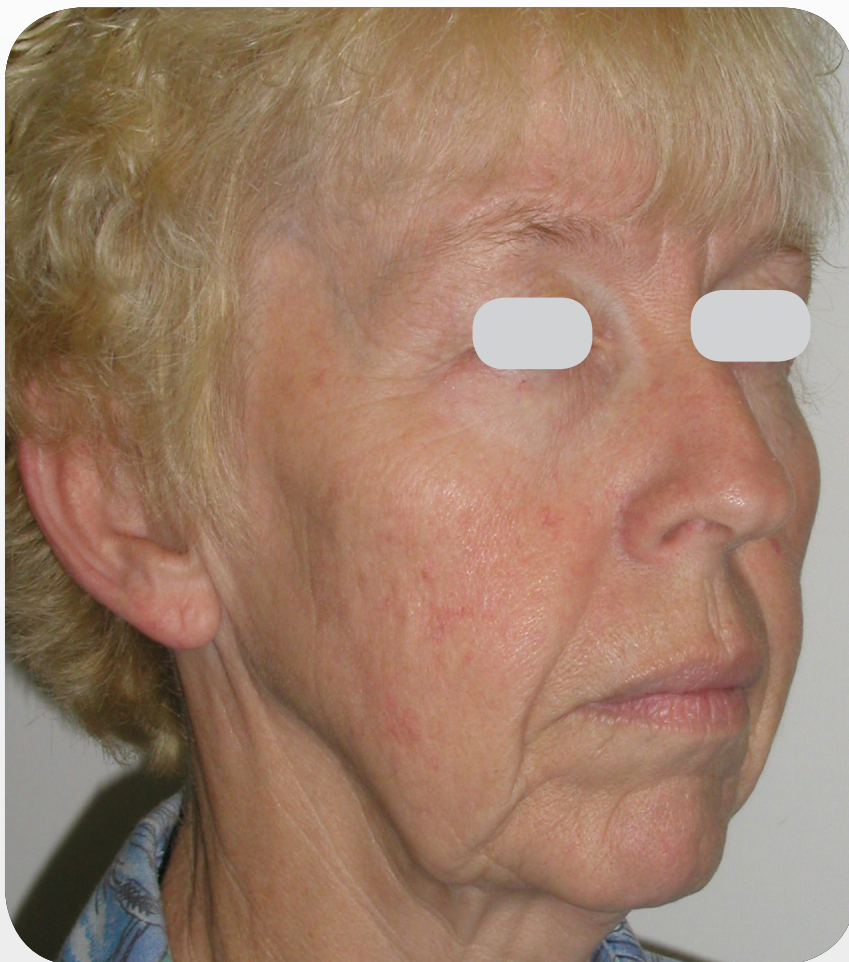

After treatment

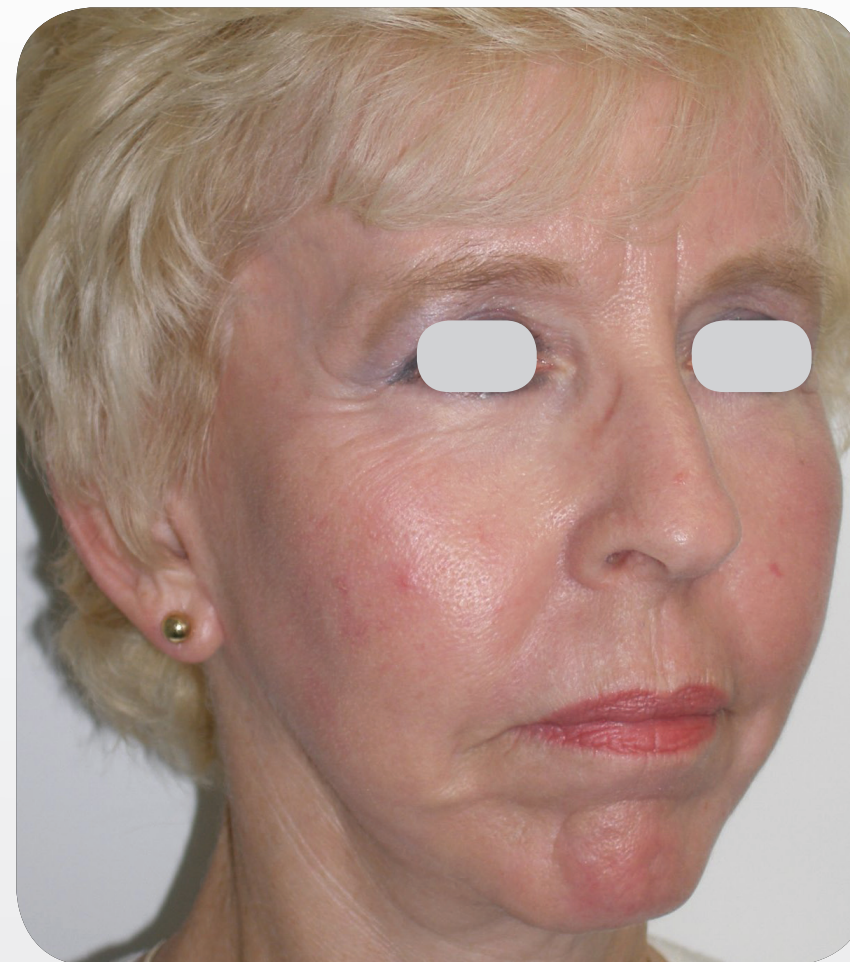Courtesy of Joseph Niamtu III, DMD

PB-1003880 Rev C

# Deep Skin Resurfacing



Baseline

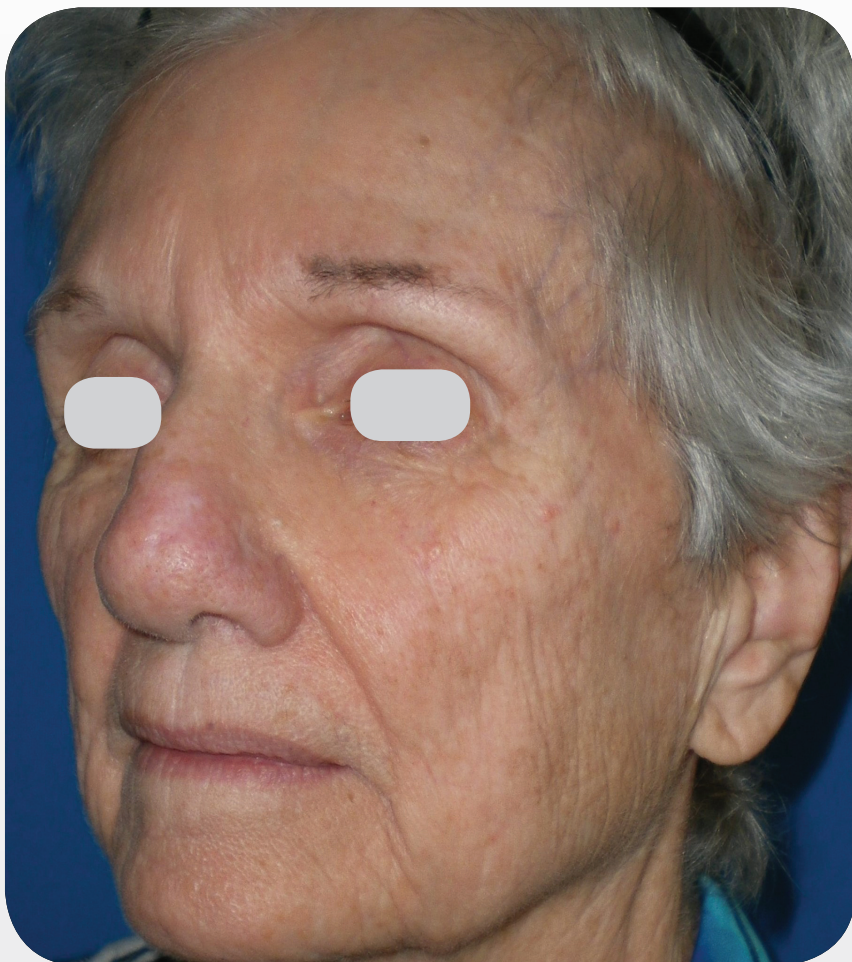


After treatment

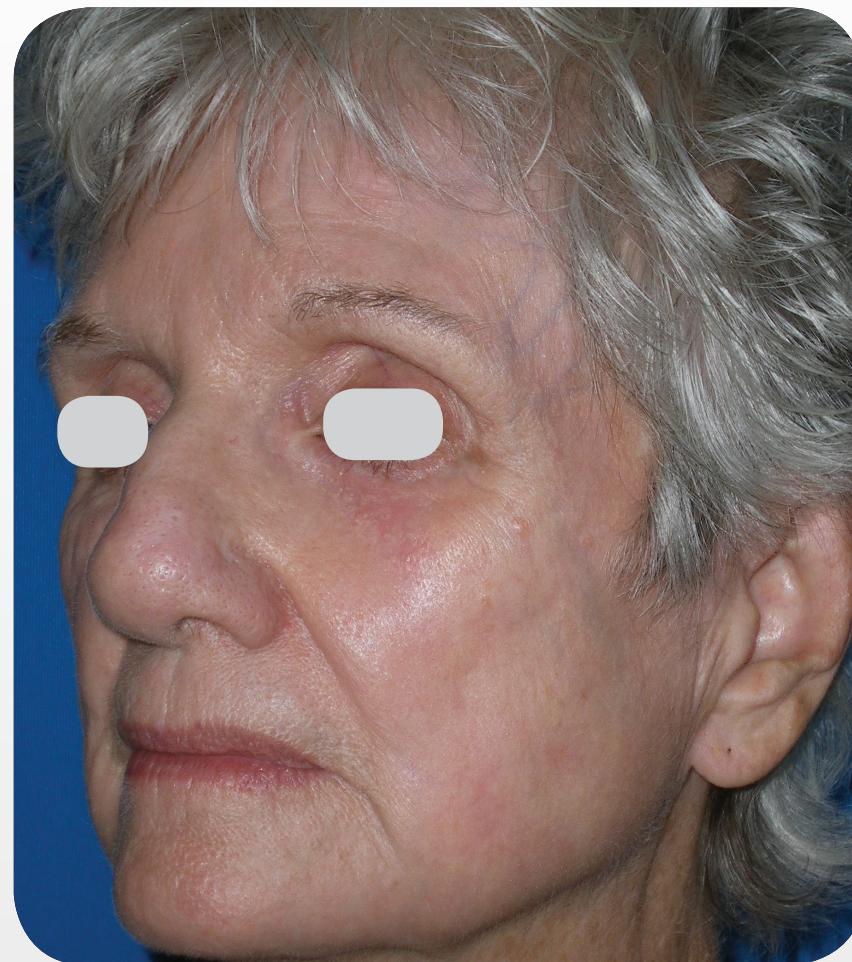Courtesy of Joseph Niamtu III, DMD

PB-1003880 Rev C

# Skin Resurfacing



Baseline



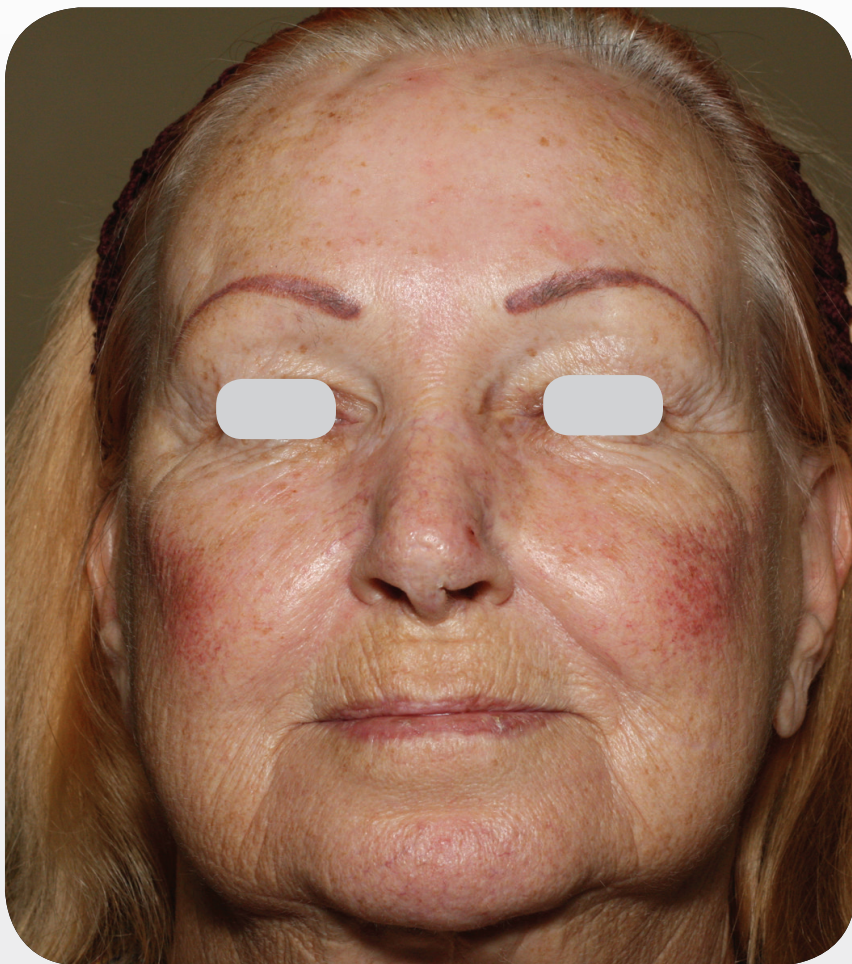After treatment

Courtesy of Joseph Niamtu III, DMD

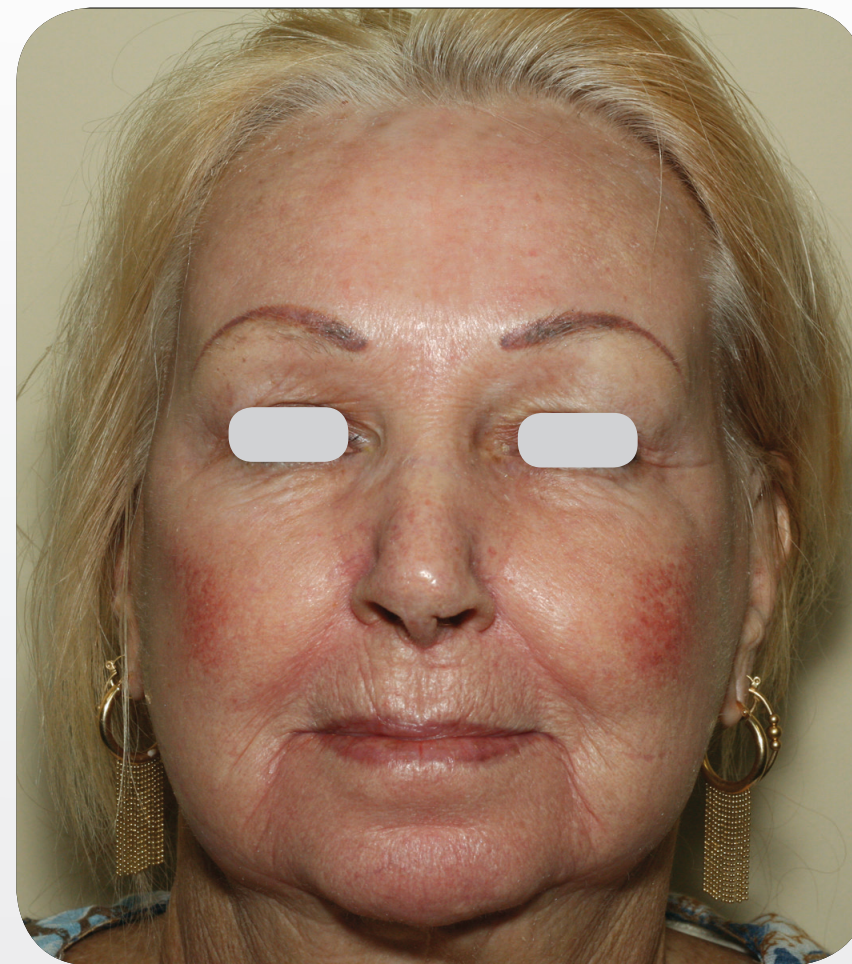PB-1003880 Rev C



# Skin Resurfacing



Baseline

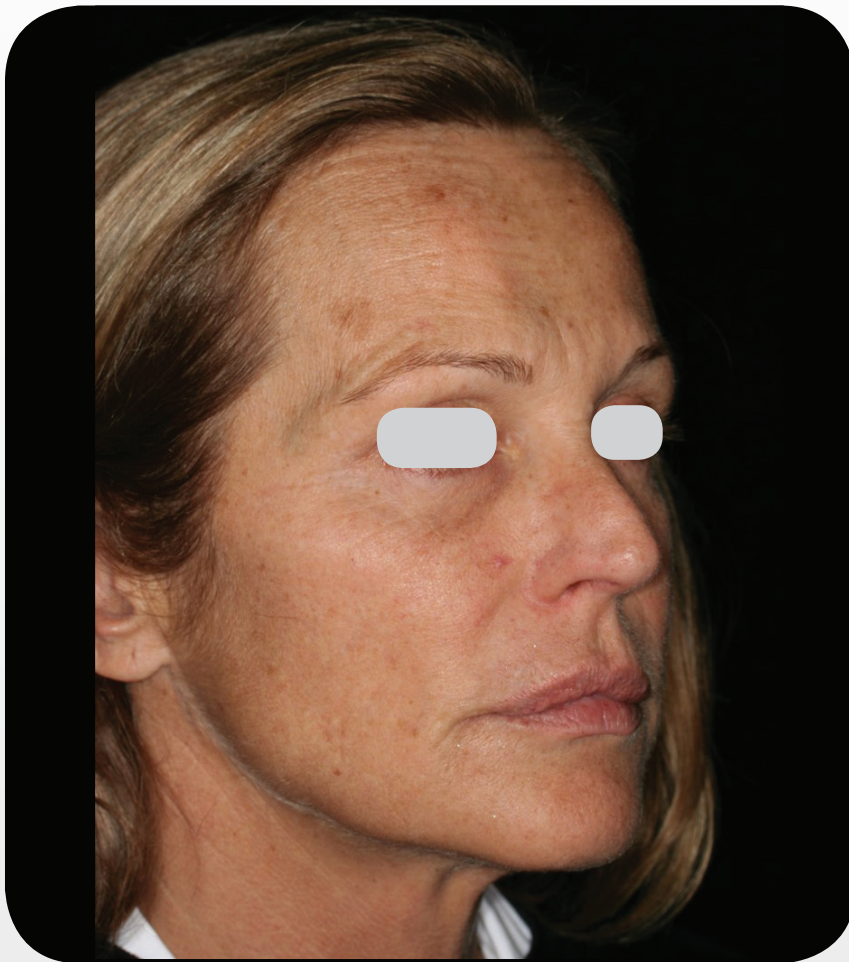

After treatment

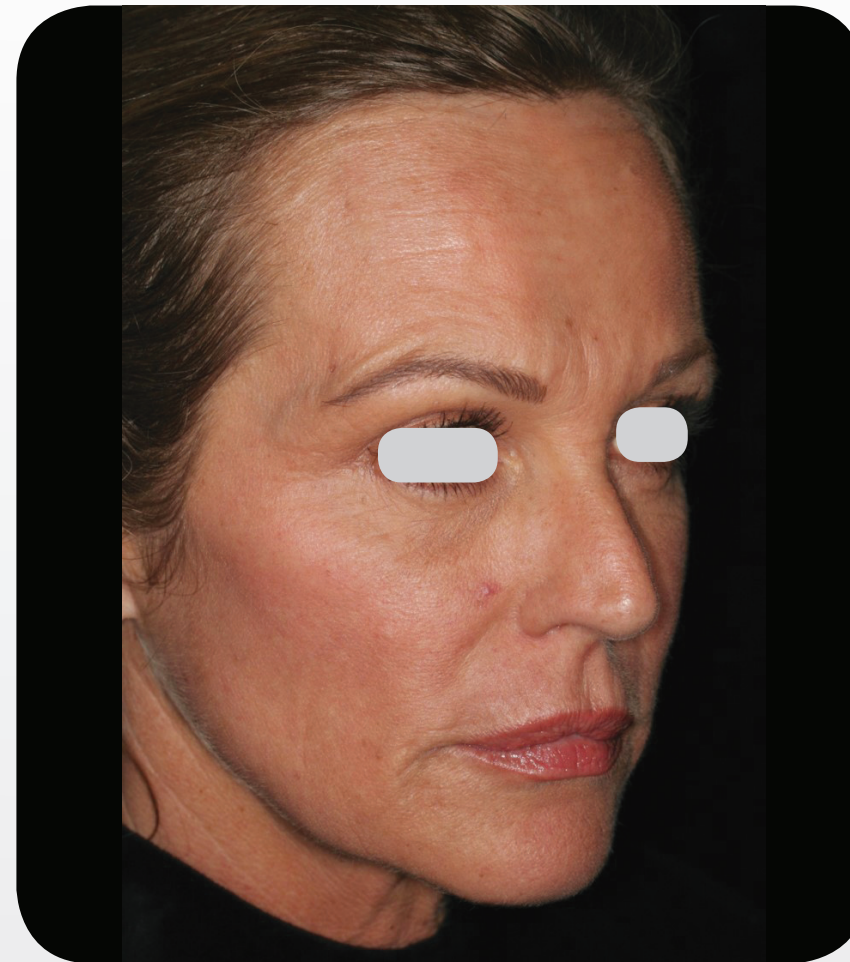Courtesy of Andrew Hector, MD

PB-1003880 Rev C

# Skin Resurfacing



Baseline

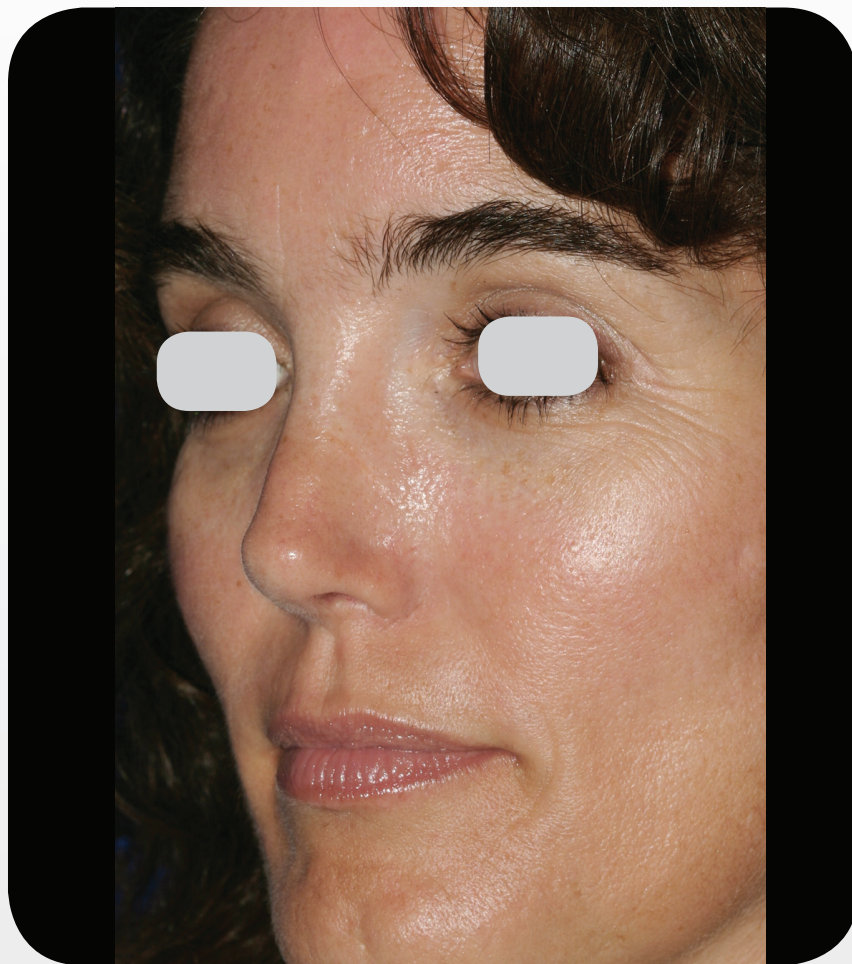

7 days after treatment

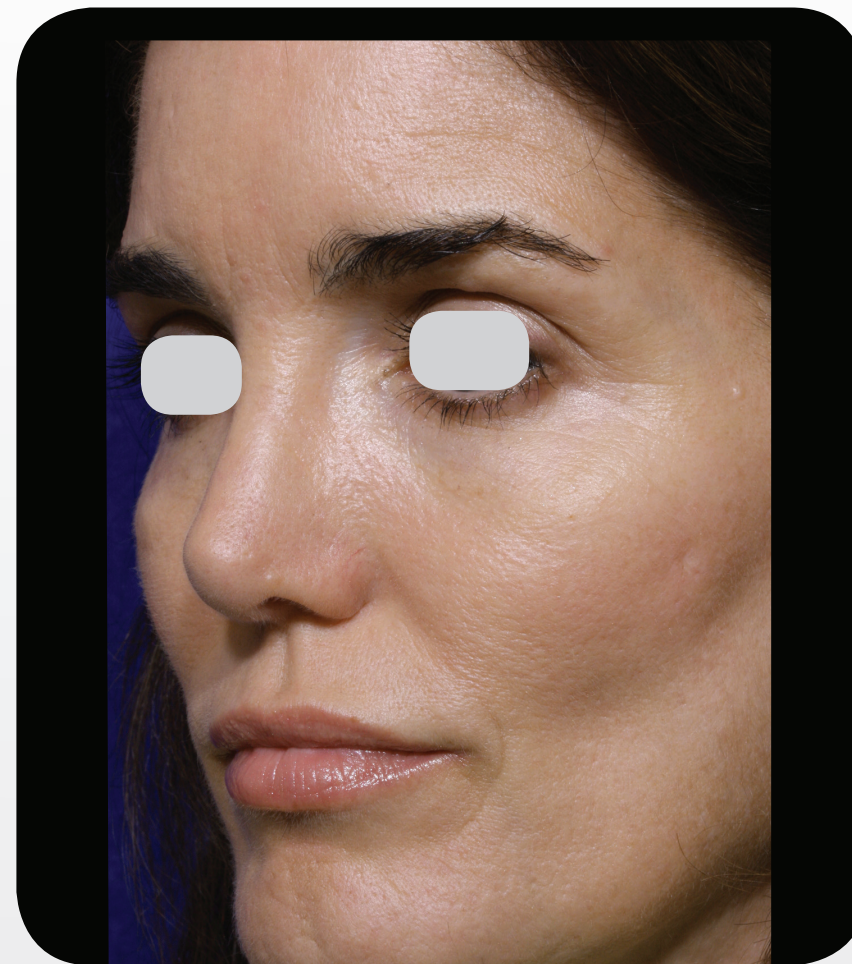Courtesy of Matteo Tretti Clementoni, MD

PB-1003880 Rev C

# Skin Resurfacing



Baseline

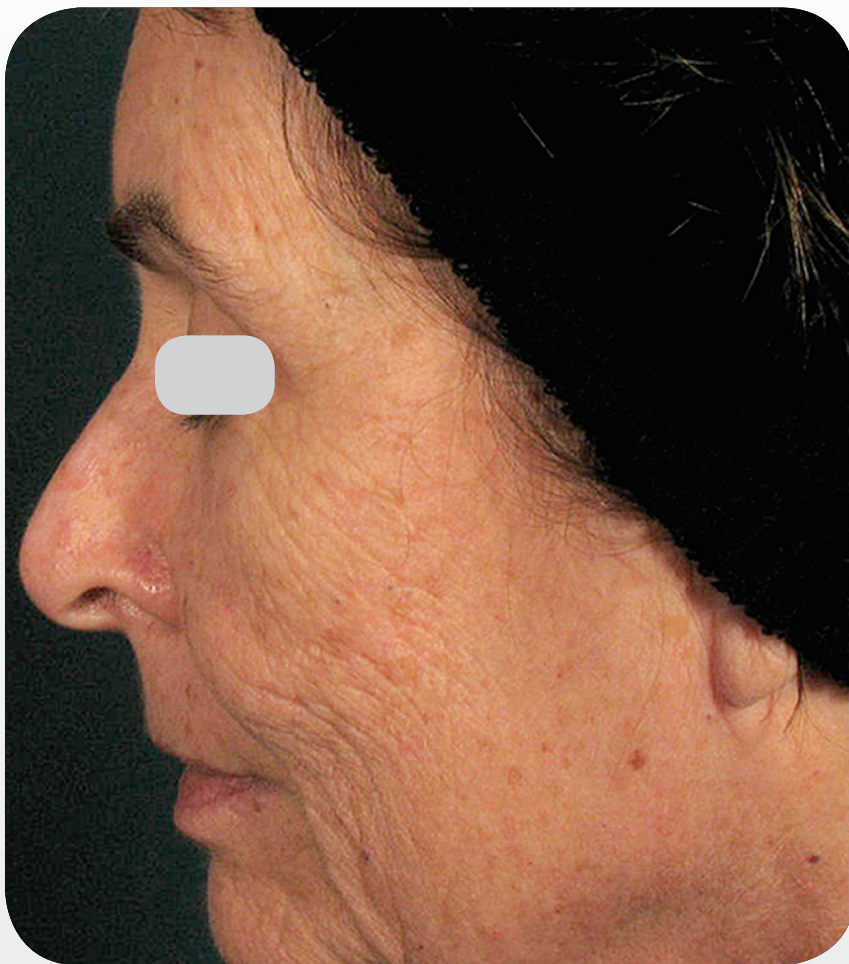

5 months after treatment

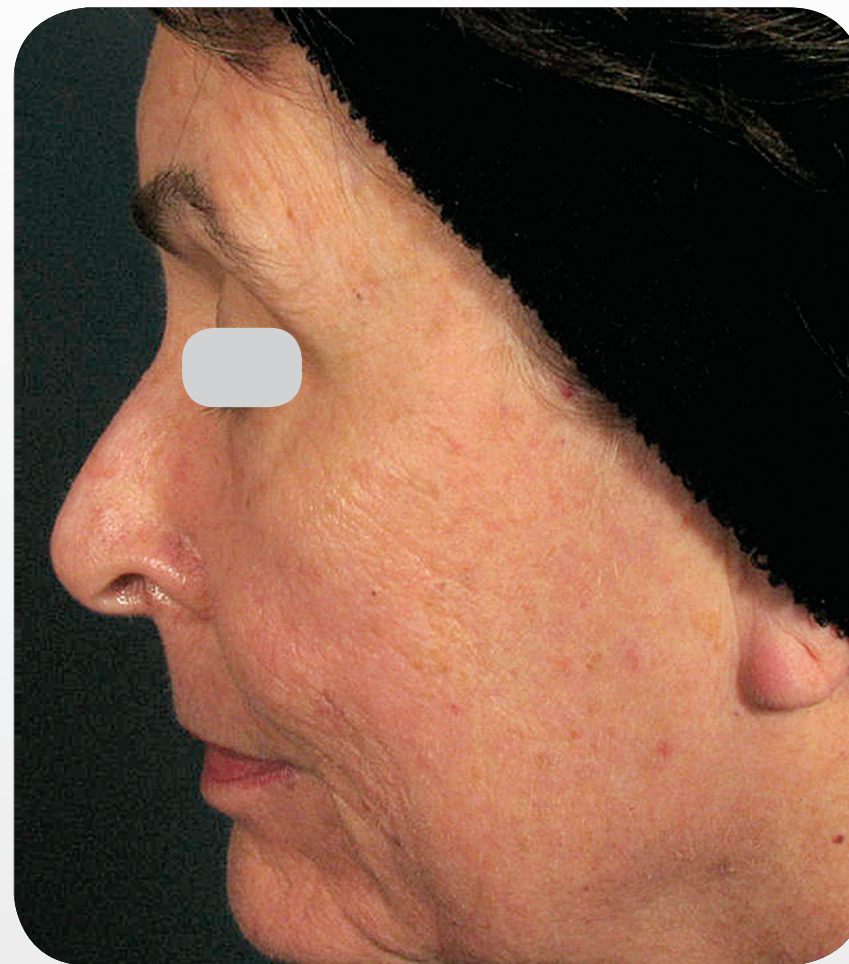Courtesy of Ivan Wayne, MD

PB-1003880 Rev C

# Skin Resurfacing



Baseline

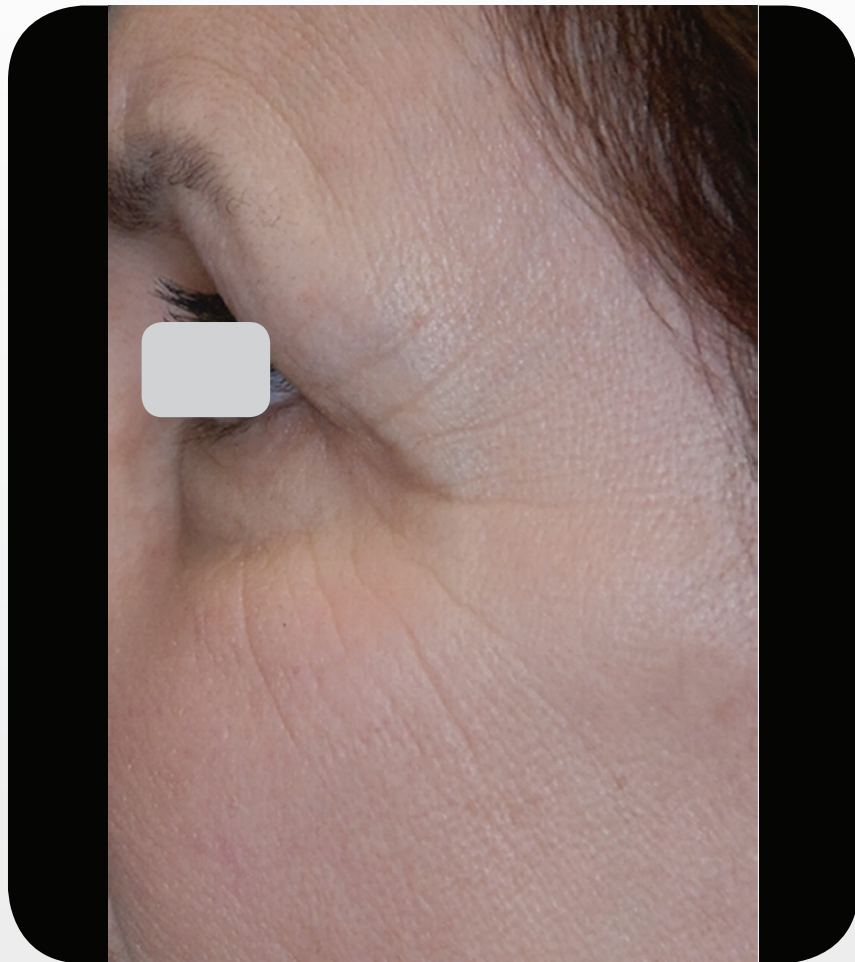


After treatment

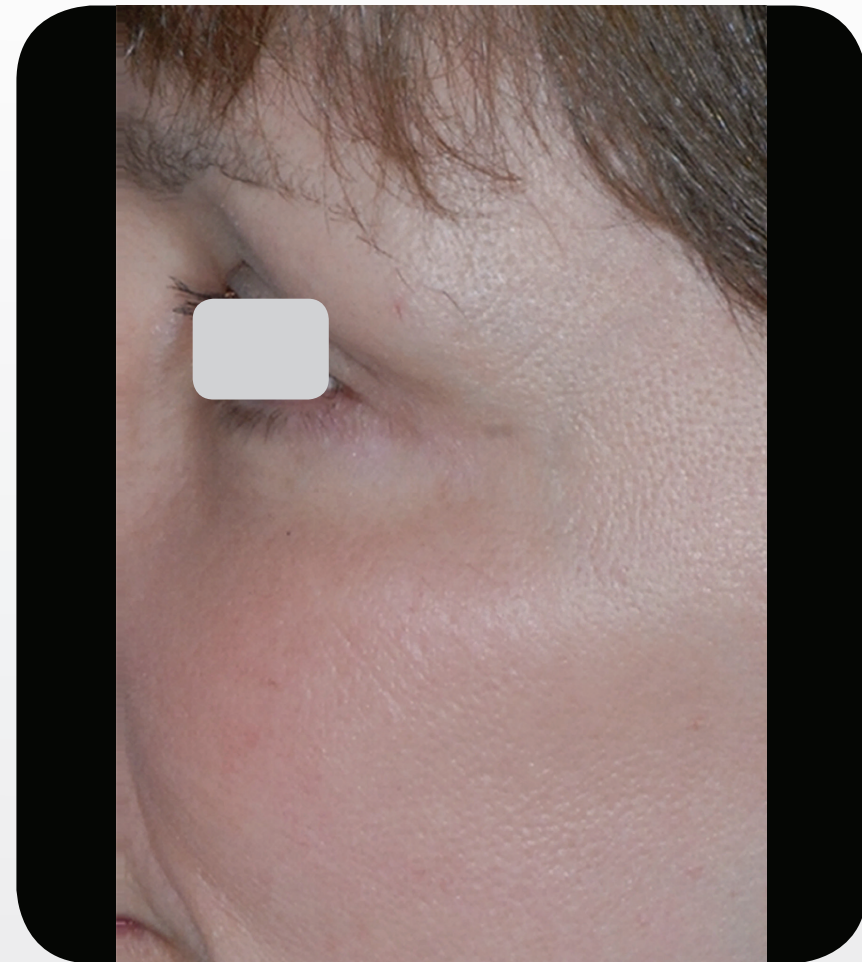Courtesy of Girish Munavalli, MD

PB-1003880 Rev C

# Periorbital Skin Resurfacing



Baseline

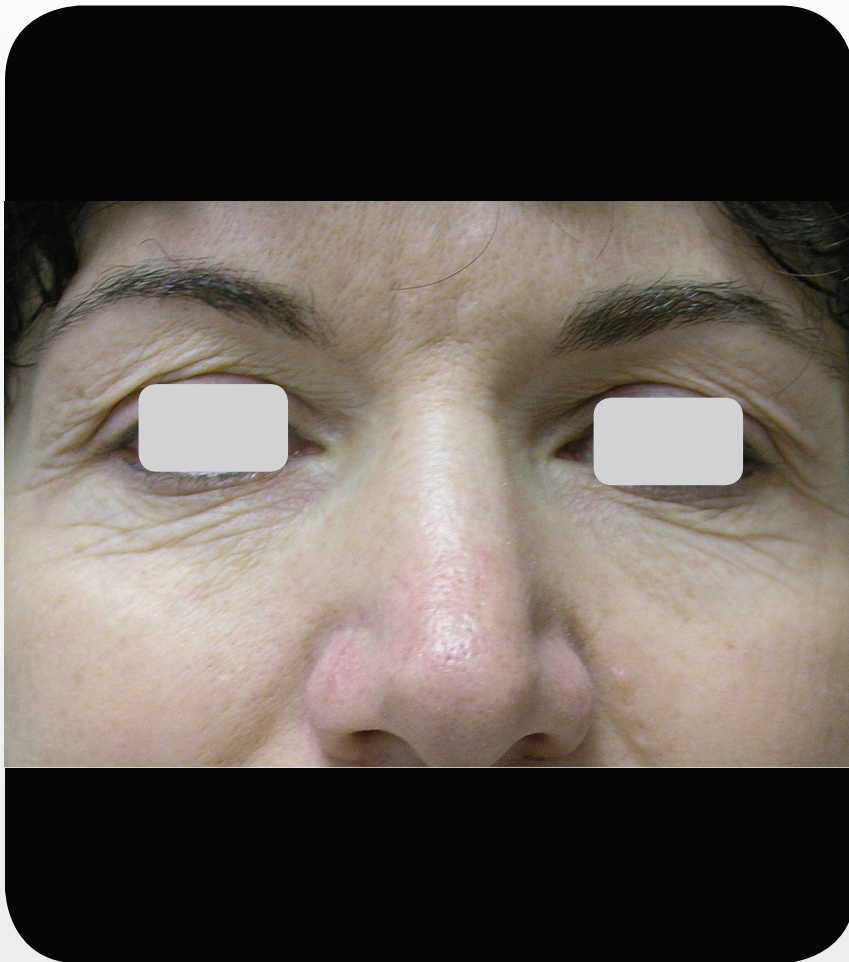

3 months after treatment

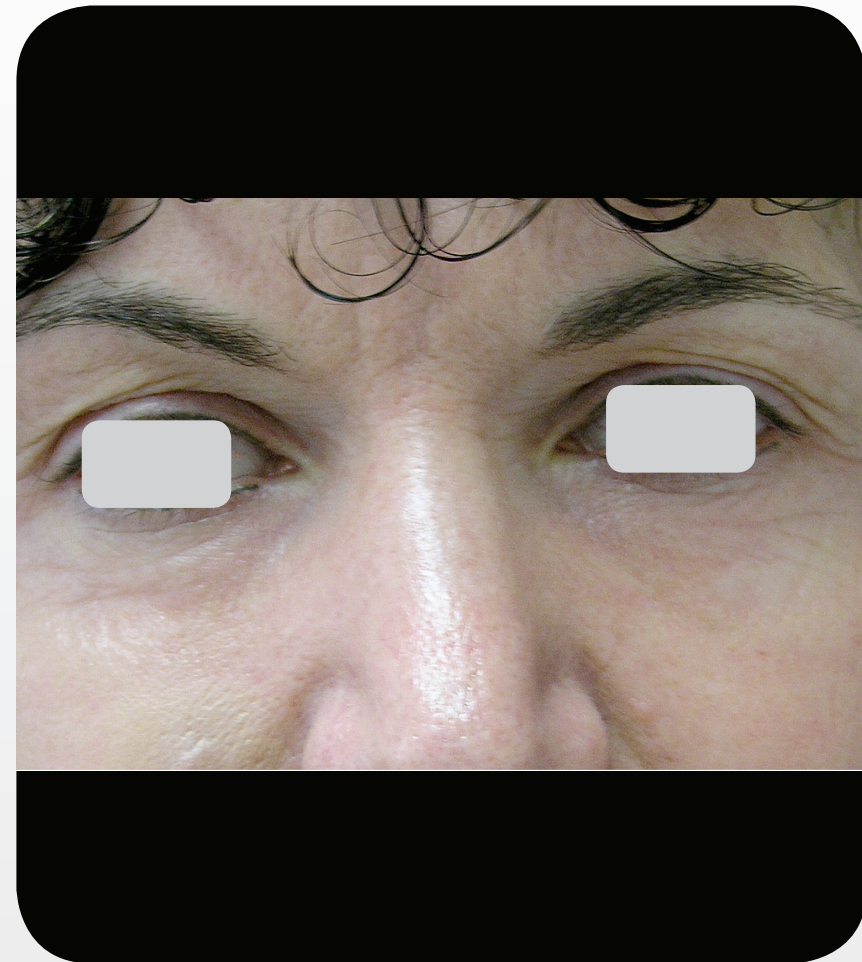Courtesy of J. Kevin Duplechain, MD

PB-1003880 Rev C

# Periorbital Skin Resurfacing



Baseline

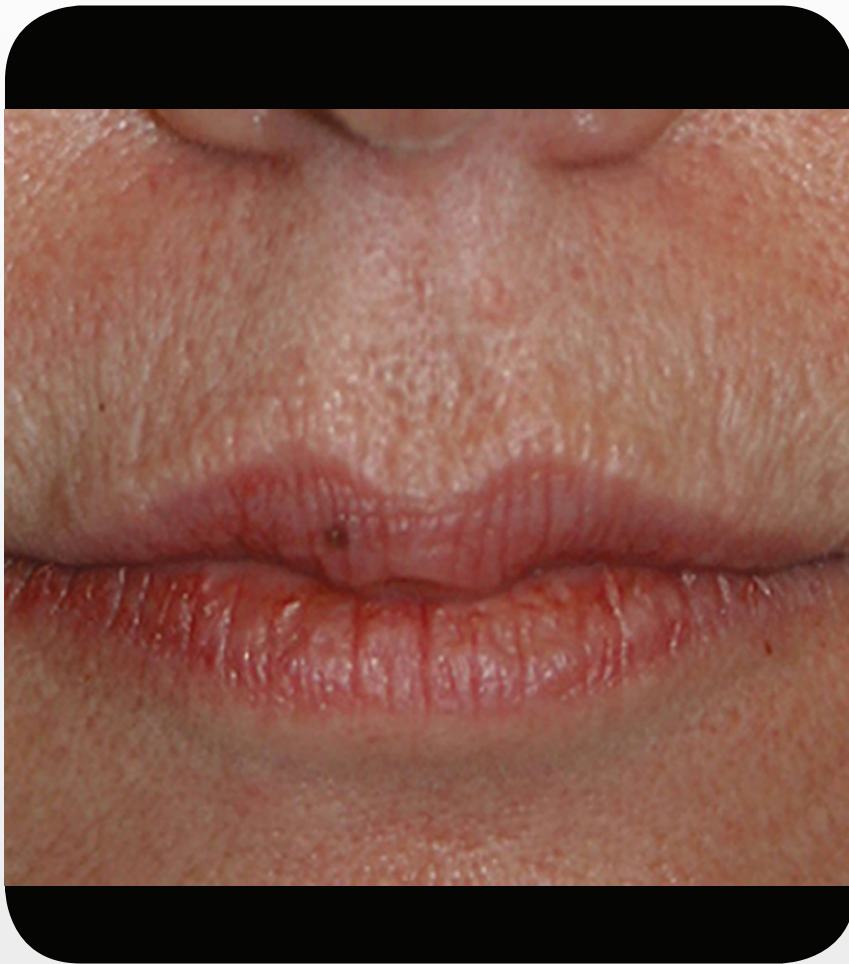

1 week after 1 treatment

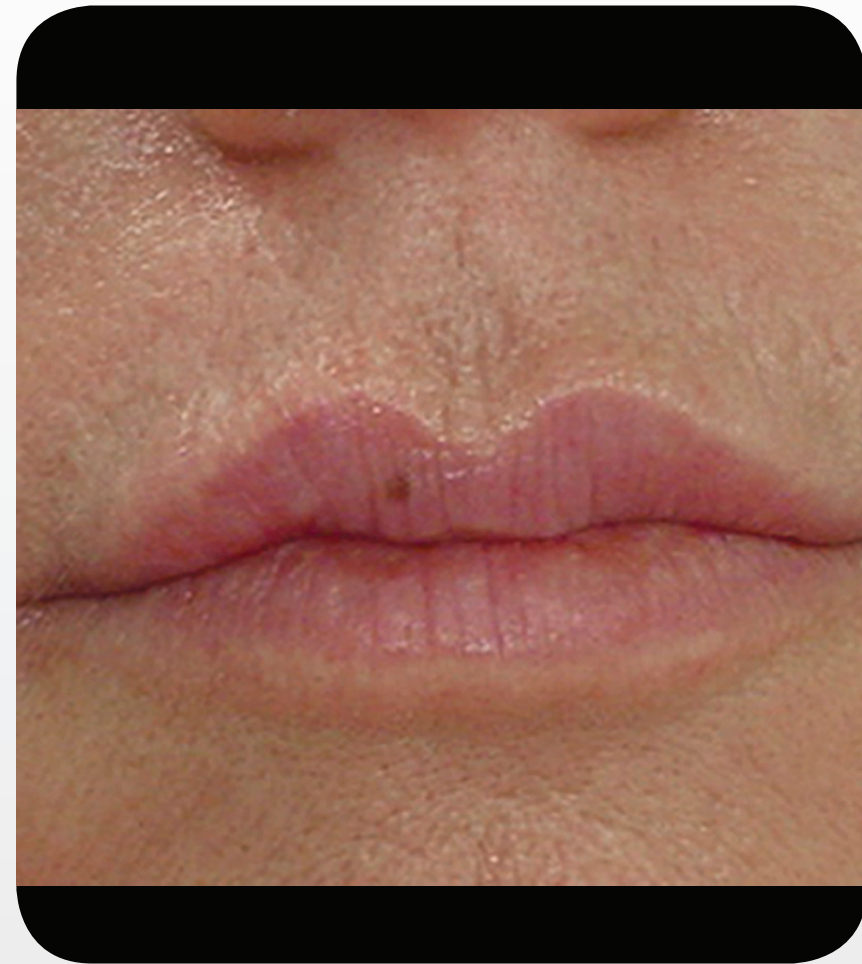Courtesy of Glenn A. DeBias, DO

PB-1003880 Rev C

# Perioral Skin Resurfacing



Baseline

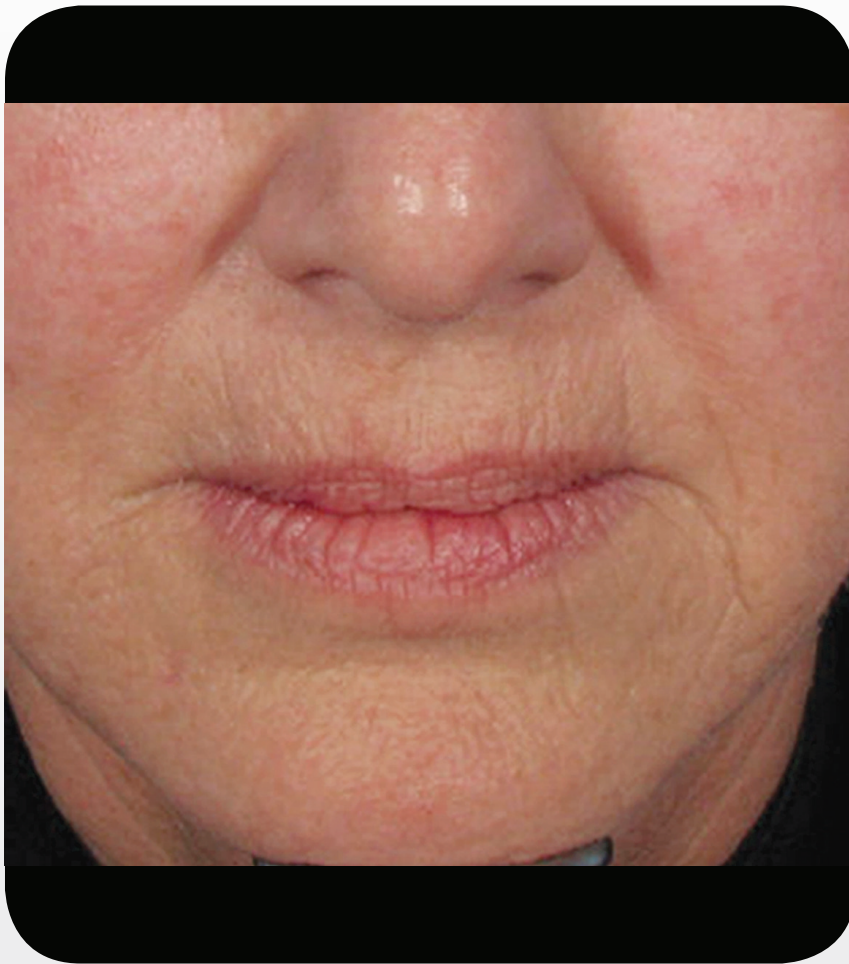

6 weeks after 1 treatment

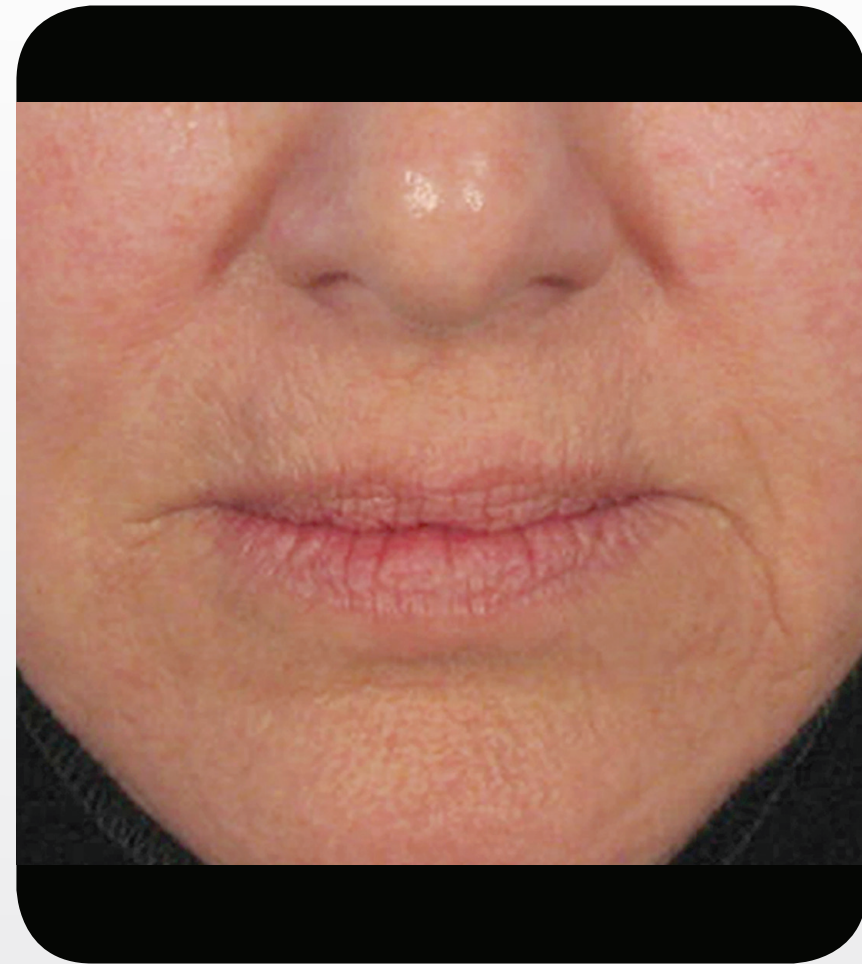Courtesy of Robert Weiss, MD

PB-1003880 Rev C

# Perioral Skin Resurfacing



Baseline



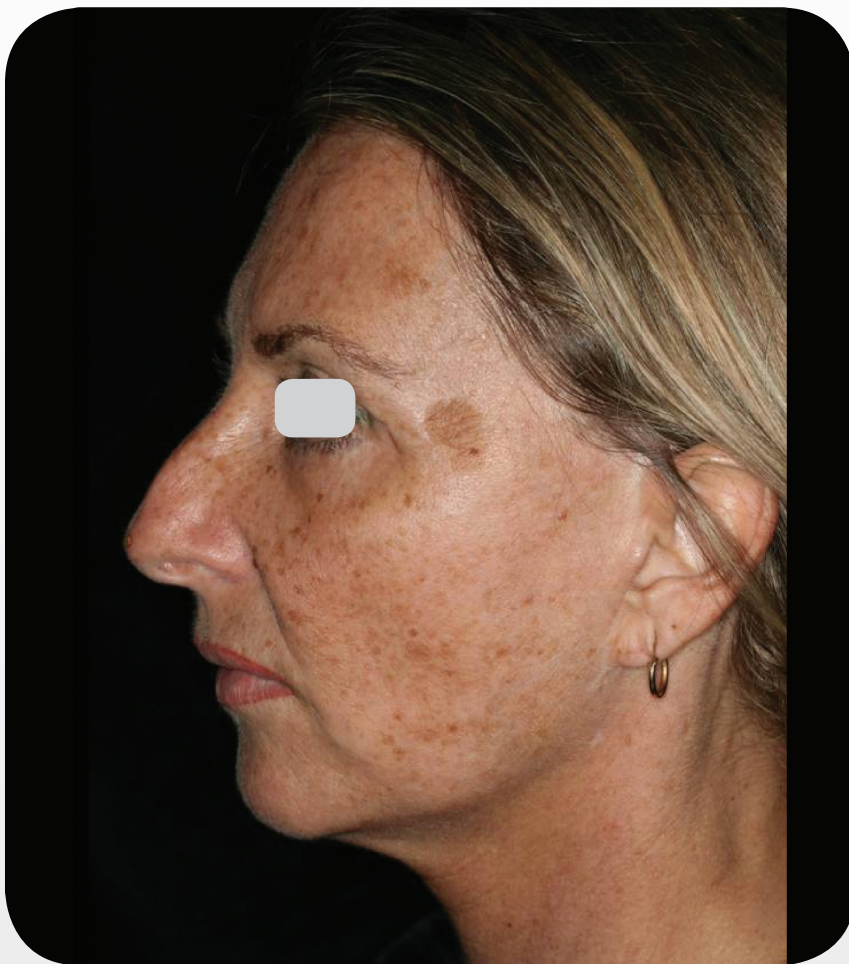20 days after 1 treatment

Courtesy of Girish Munavalli, MD

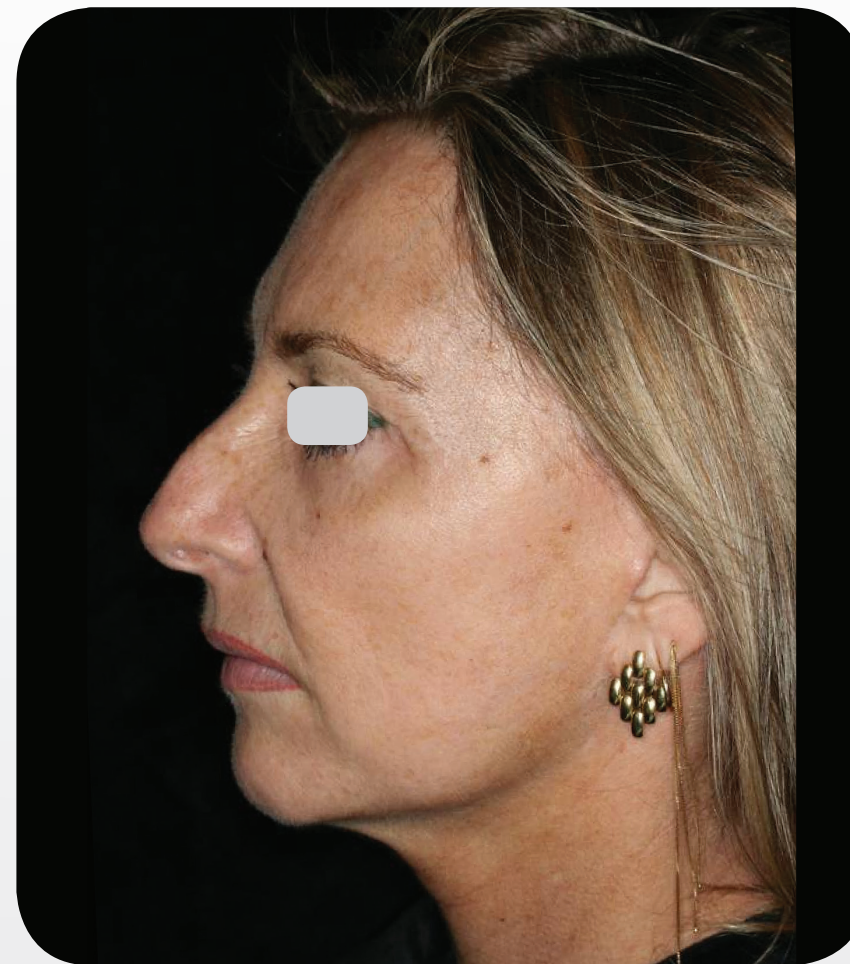PB-1003880 Rev C



# Dyschromia



Baseline

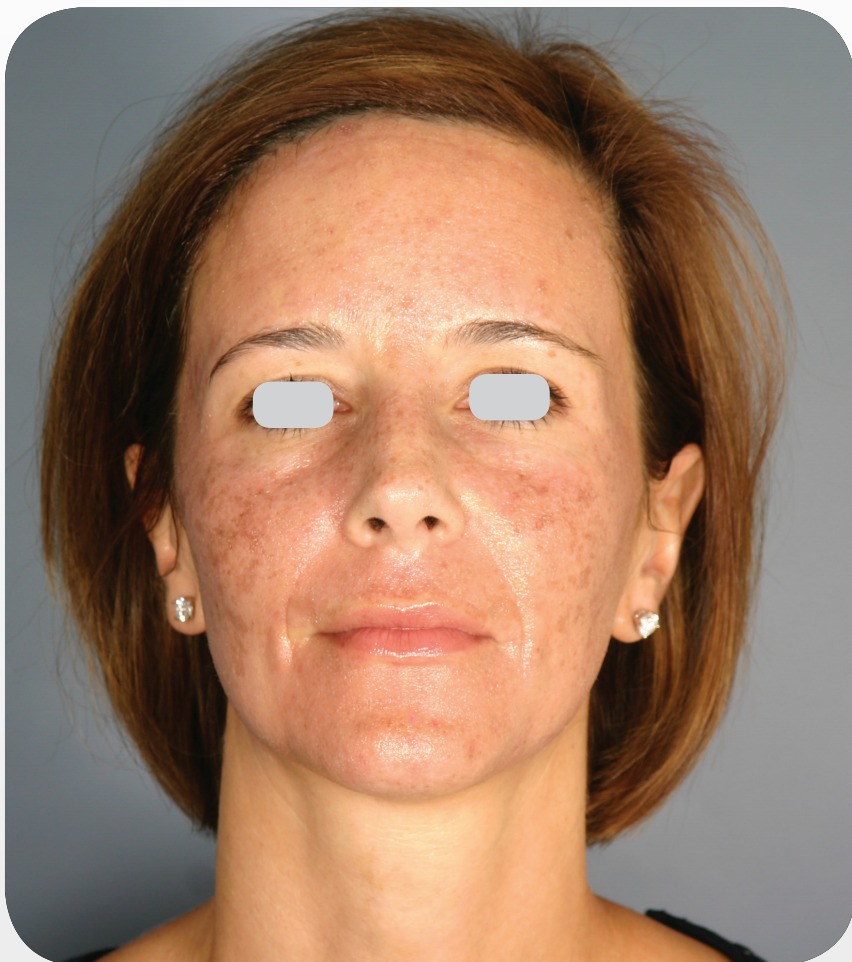

1 month after treatment

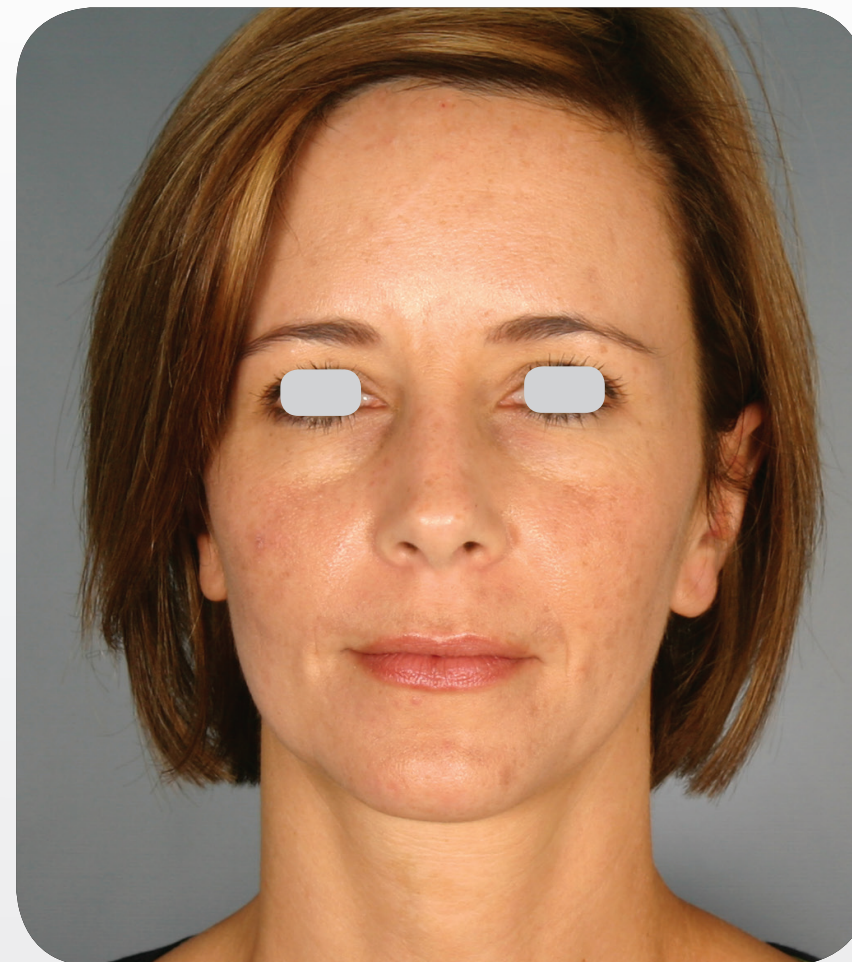
Courtesy of Matteo Tretti Clementoni, MD

PB-1003880 Rev C

# Dyschromia



Baseline

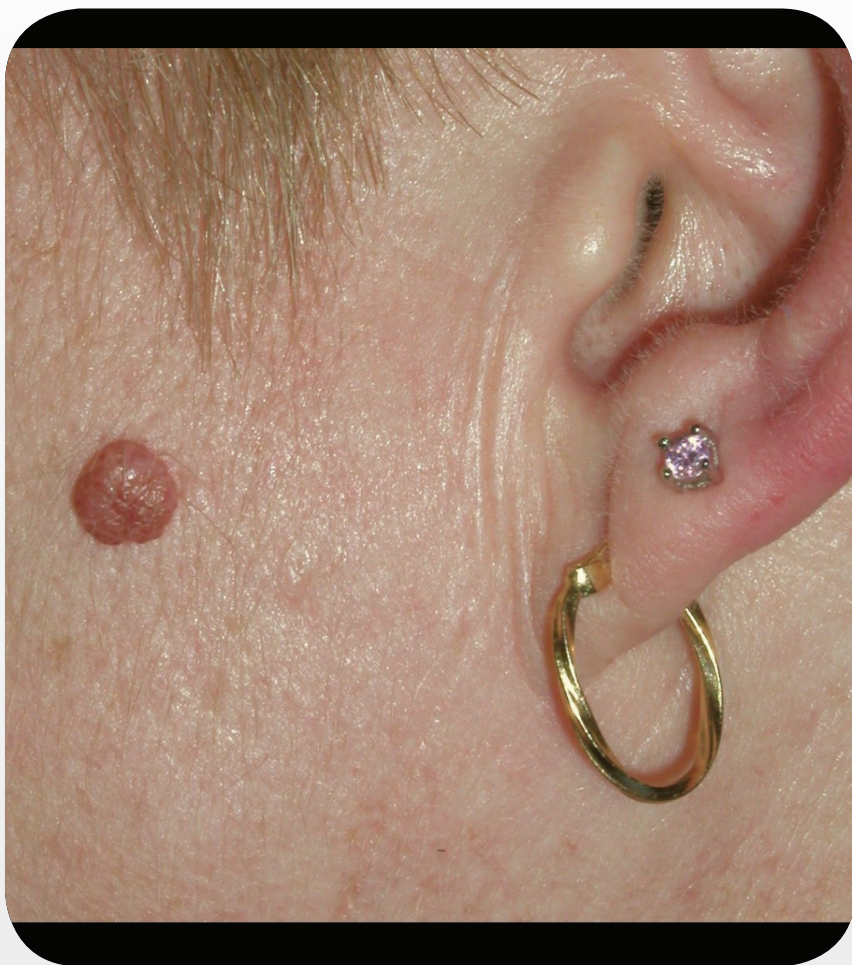

After treatment

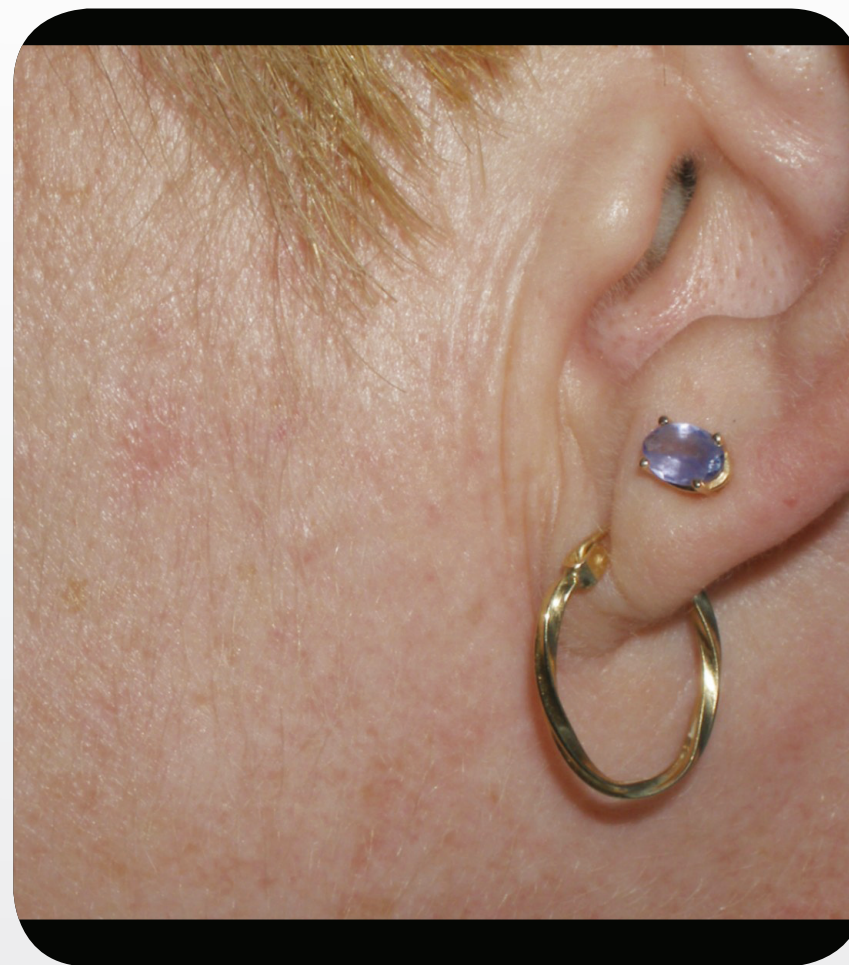Courtesy of David Kaufman, MD

PB-1003880 Rev C

# Keratoses



Baseline

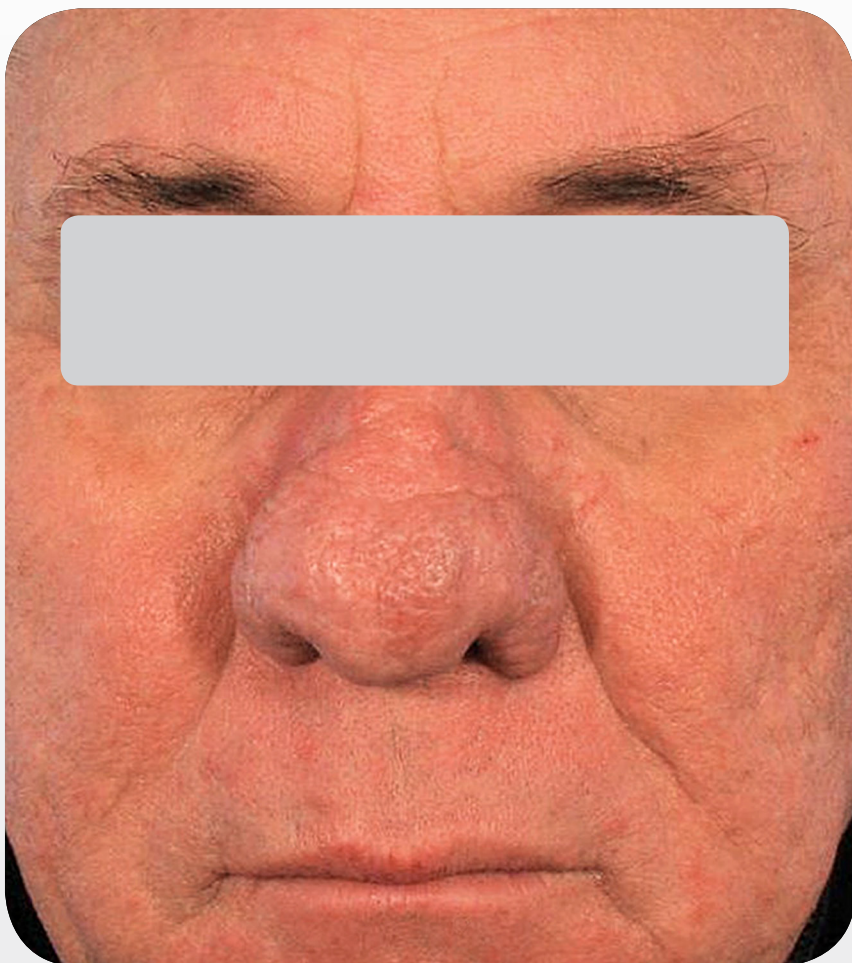


After treatment

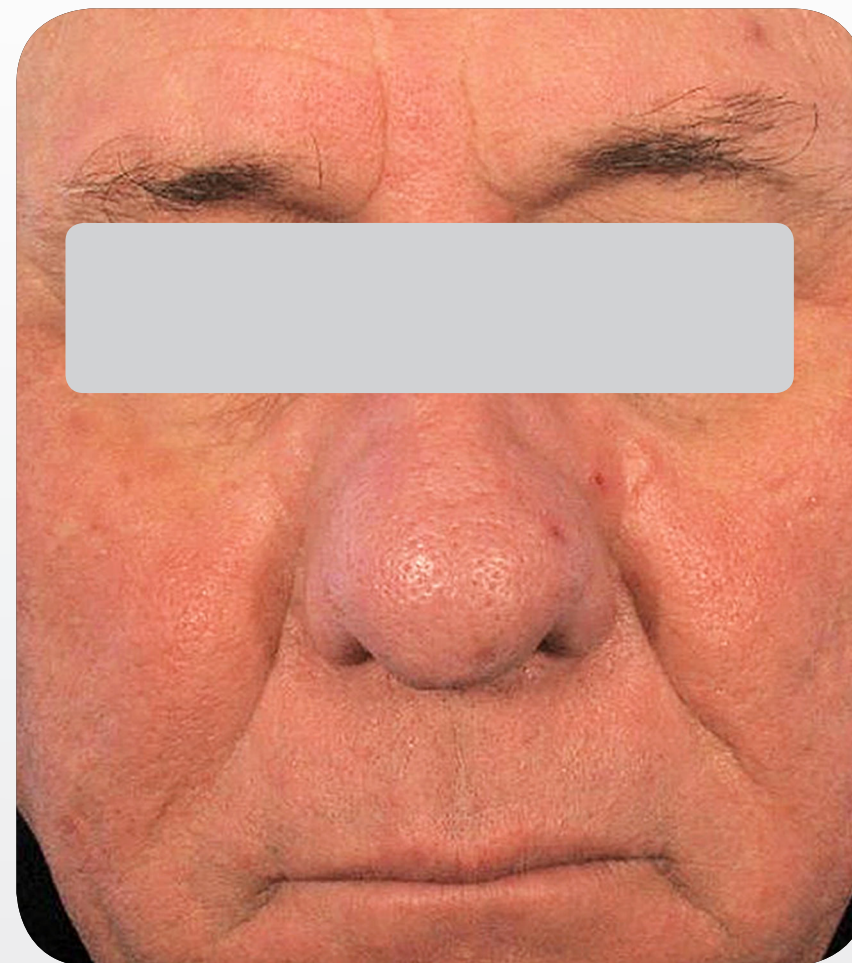
Courtesy of Joseph Niamtu III, DMD

PB-1003880 Rev C

# Rhinophyma



Baseline

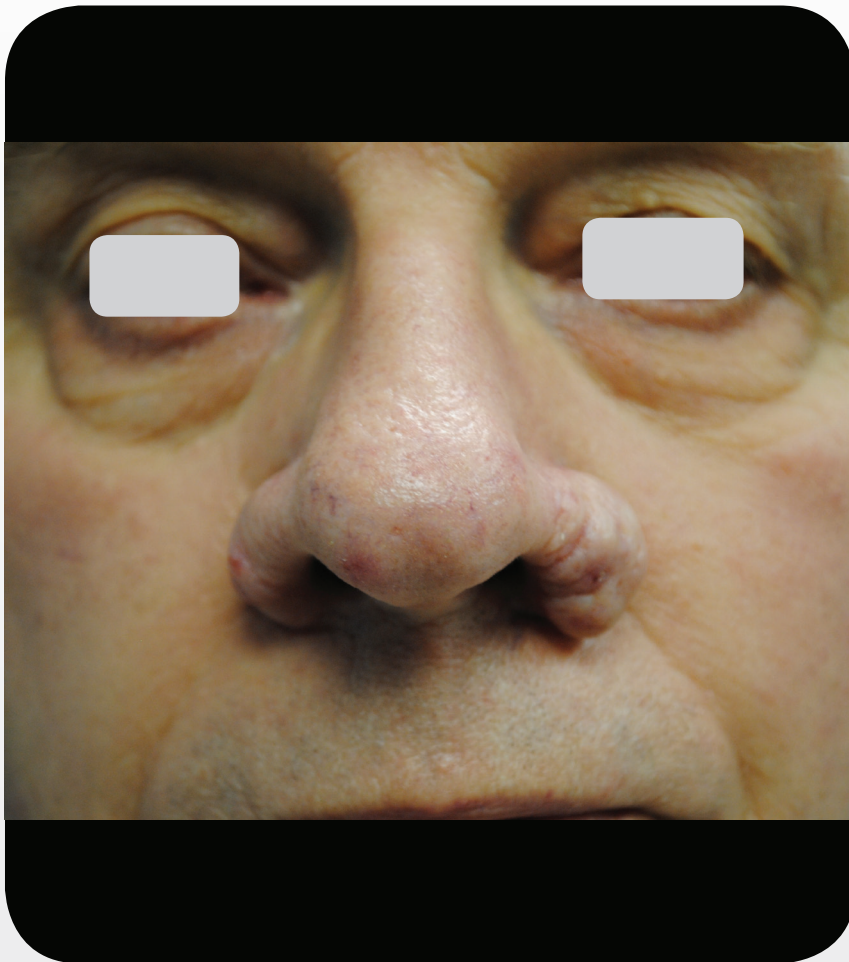


5 months after 1 treatment

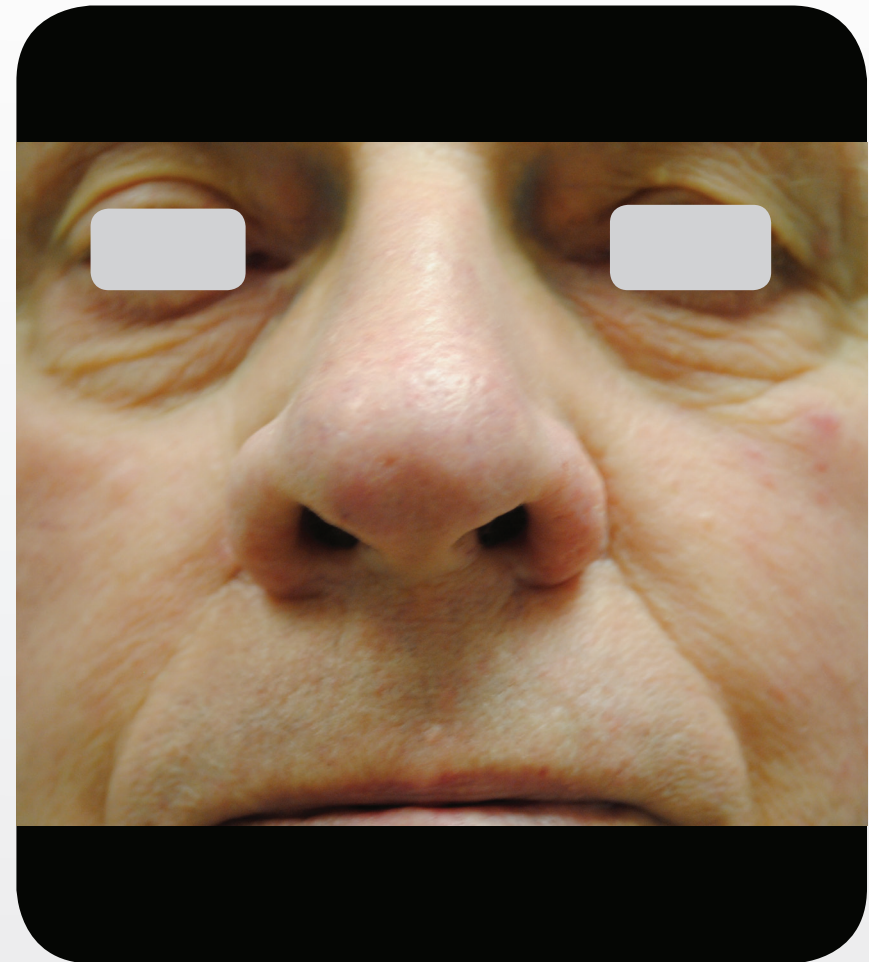
Courtesy of Girish Munavalli, MD

PB-1003880 Rev C

# Rhinophyma



Baseline

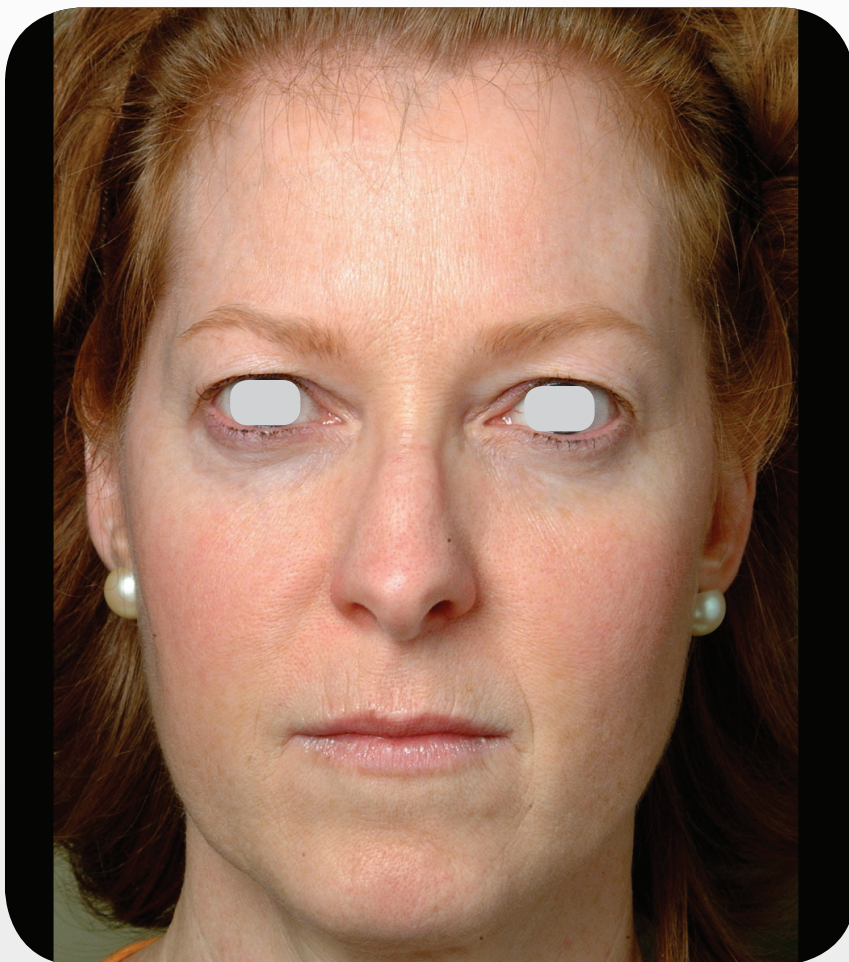

10 weeks after 1 treatment

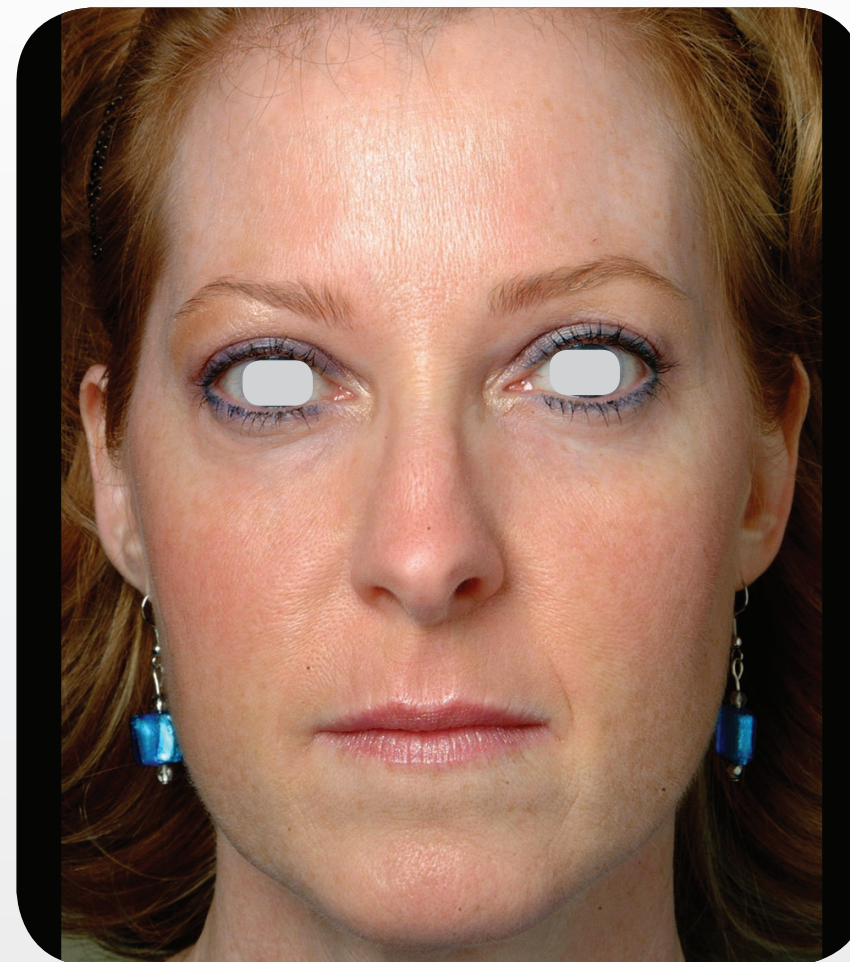Courtesy of Michael Ardabili, MD

PB-1003880 Rev C

# Blepharoplasty



Baseline

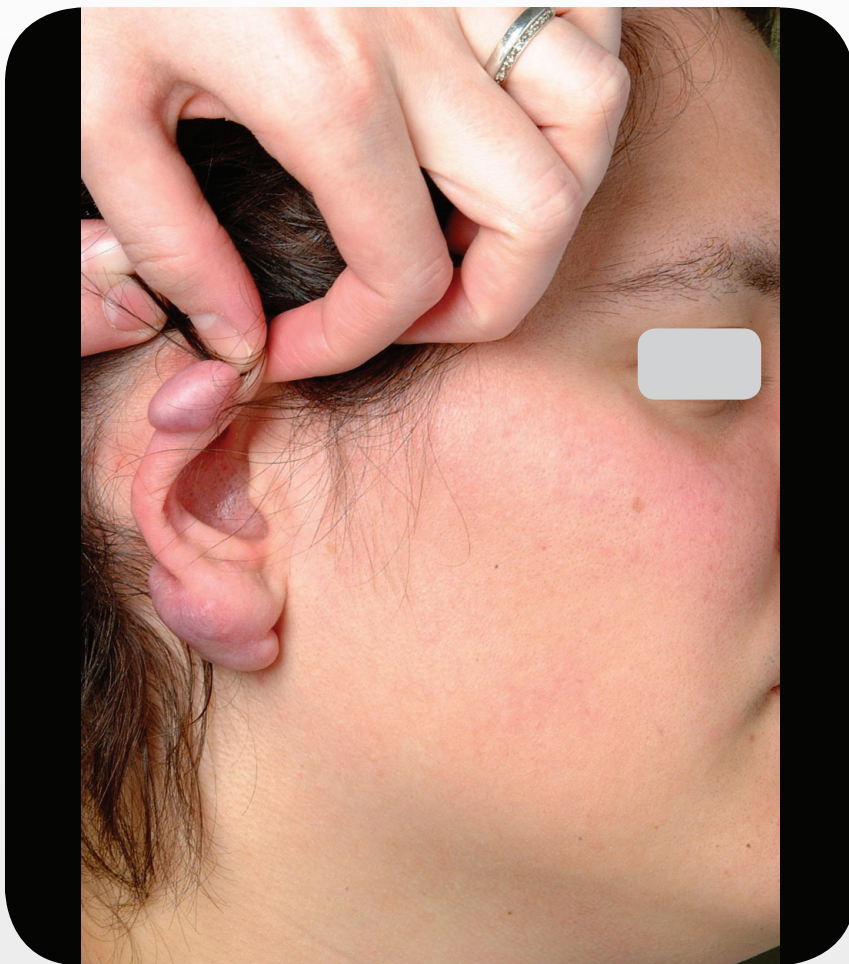


After treatment

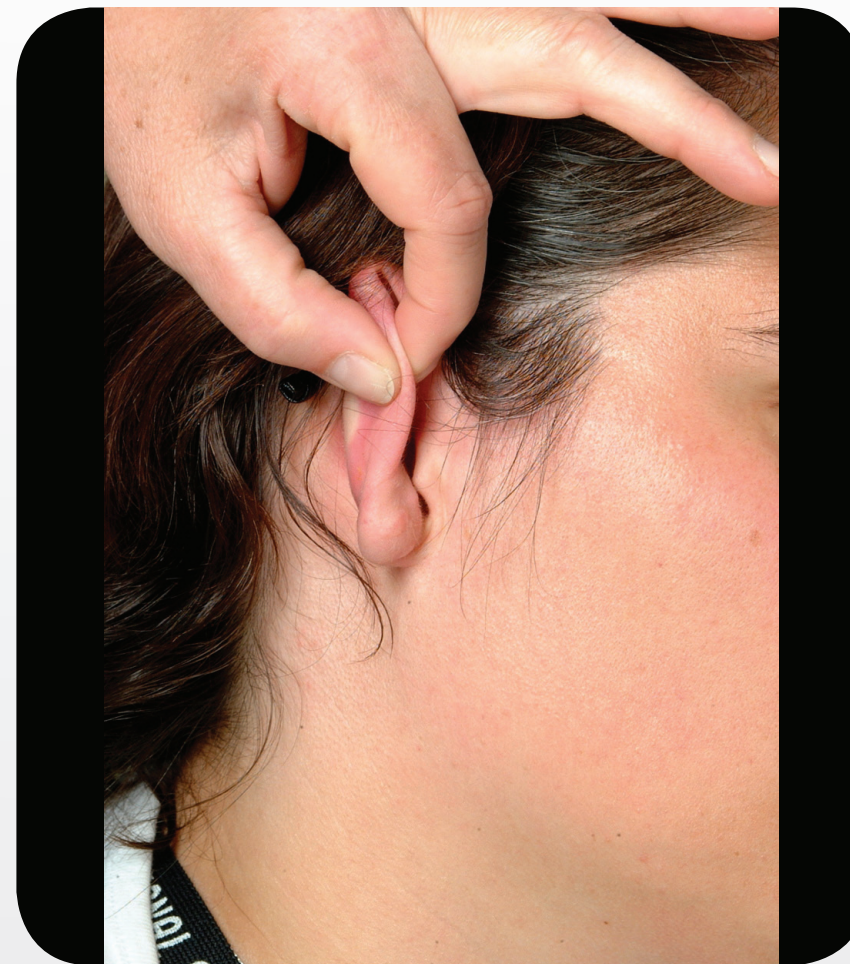Courtesy of Kent Remington, MD

PB-1003880 Rev C

# Scar Revision



Baseline

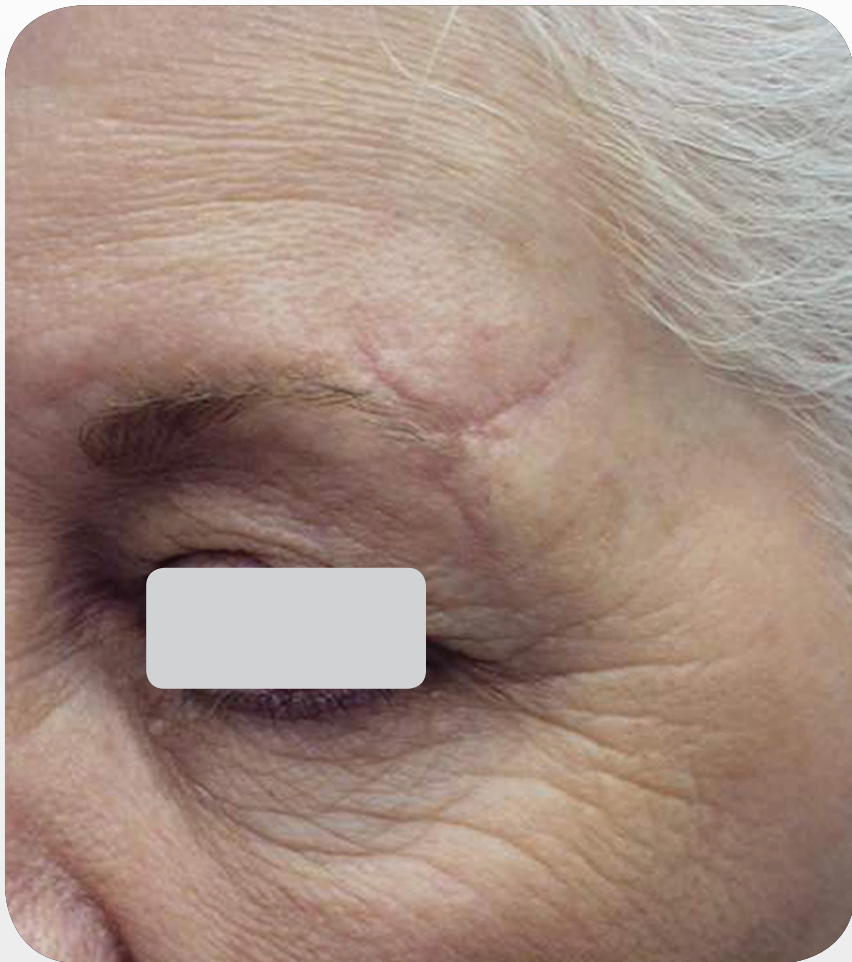

After treatment

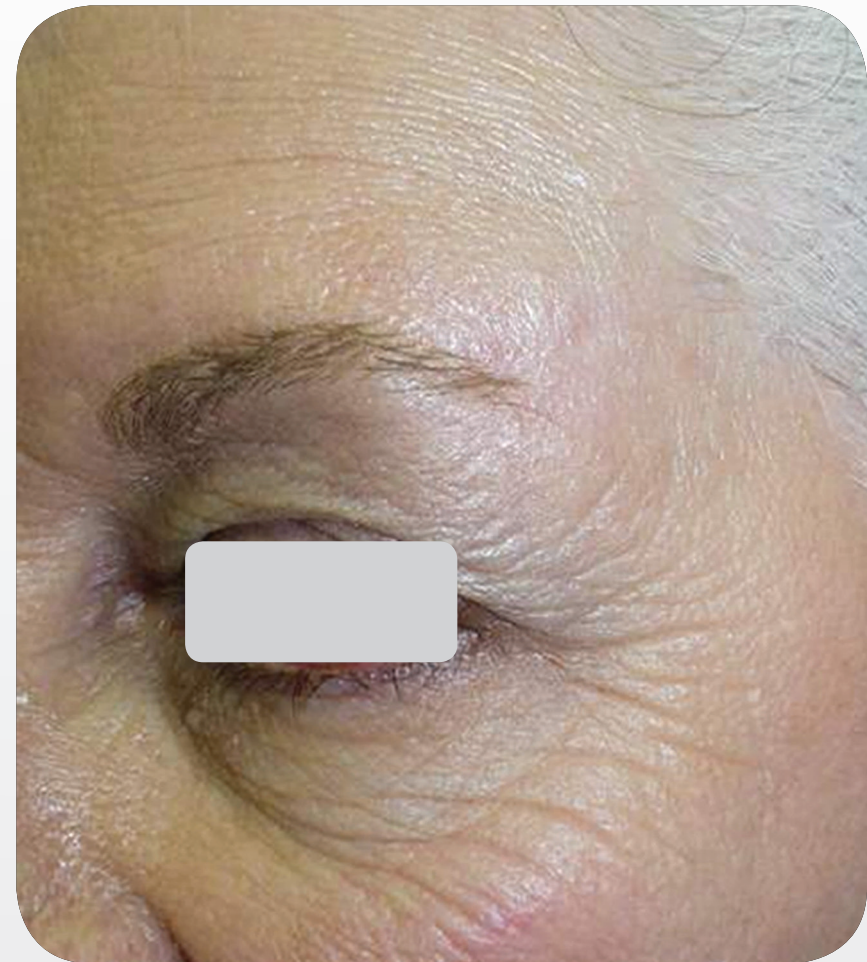Courtesy of Kent Remington, MD

PB-1003880 Rev C

# Scar Revision



Baseline



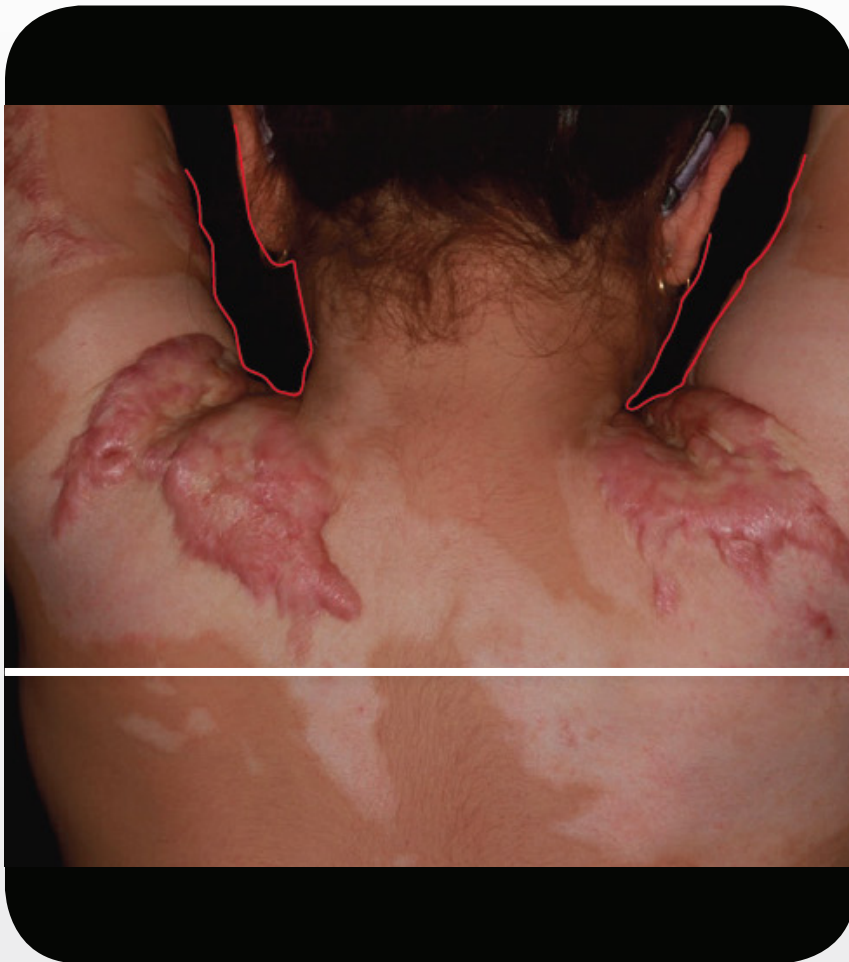After treatment

Courtesy of Joseph Niamtu III, DMD

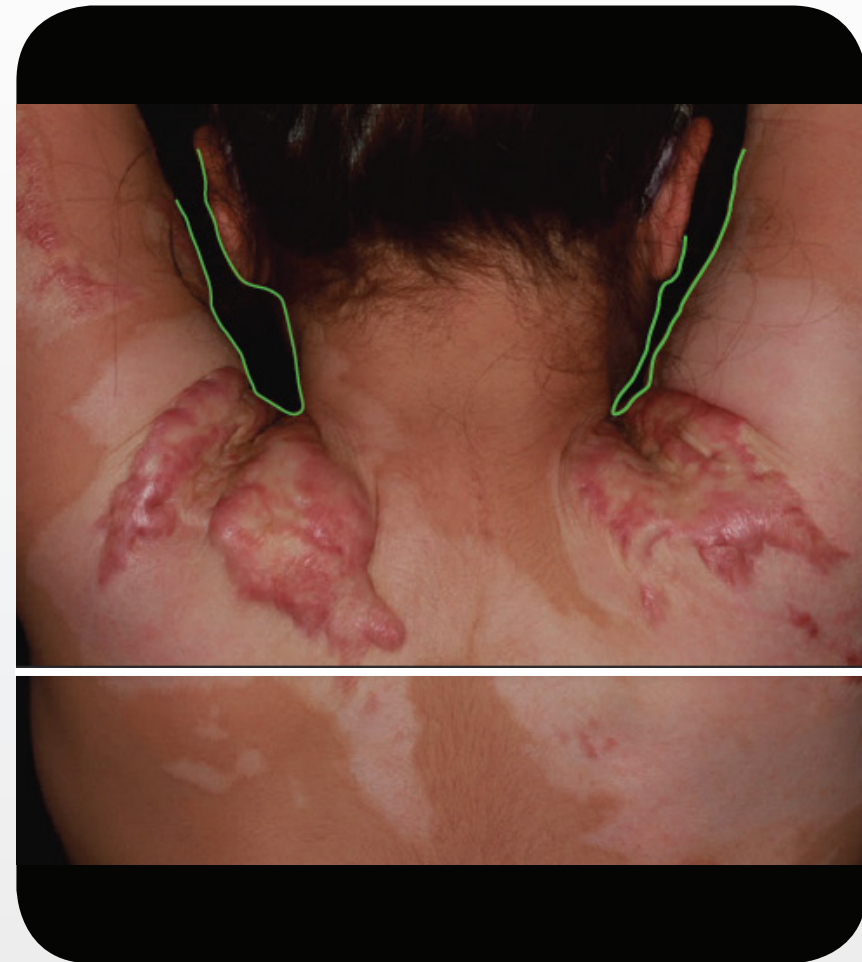PB-1003880 Rev C



# Scar Revision



Baseline

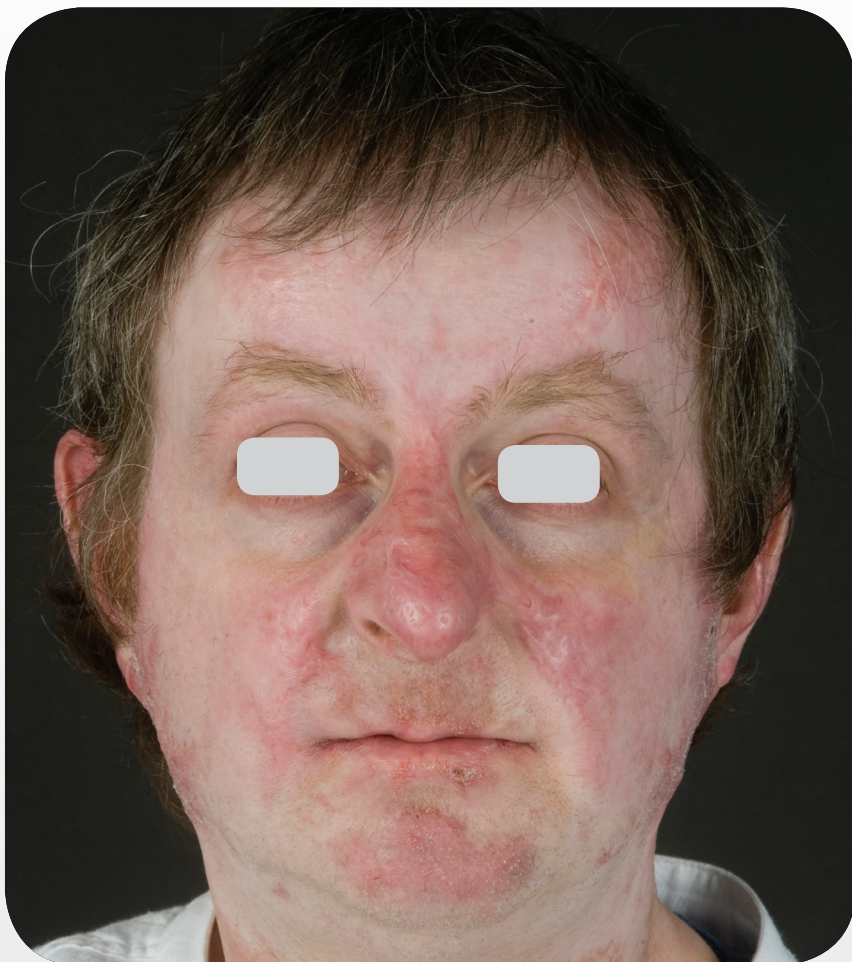

After 1 treatment

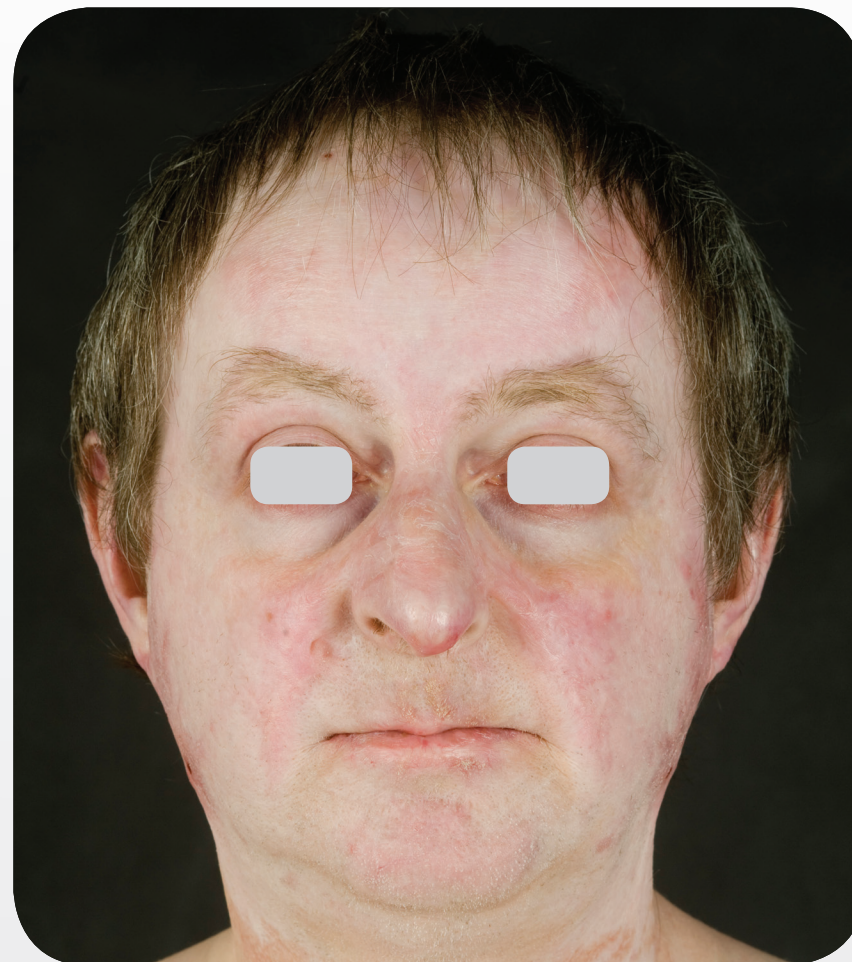
Courtesy of Matteo Tretti Clementoni, MD

PB-1003880 Rev C

# Scar Revision



Baseline

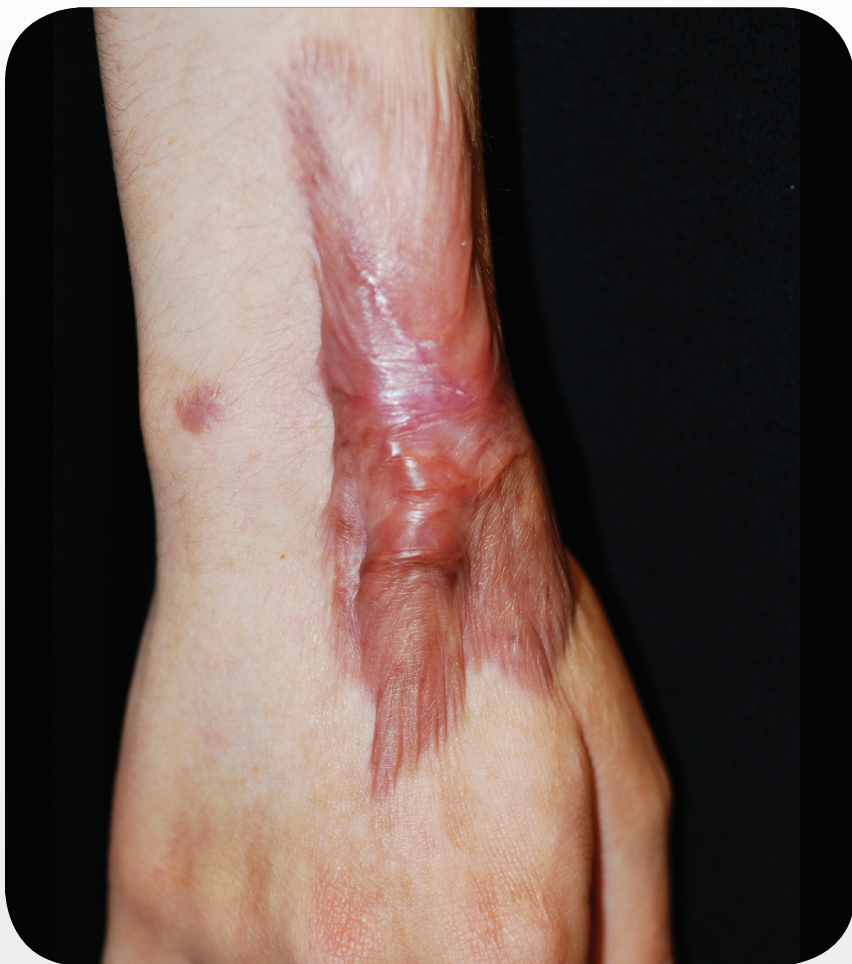

After treatment

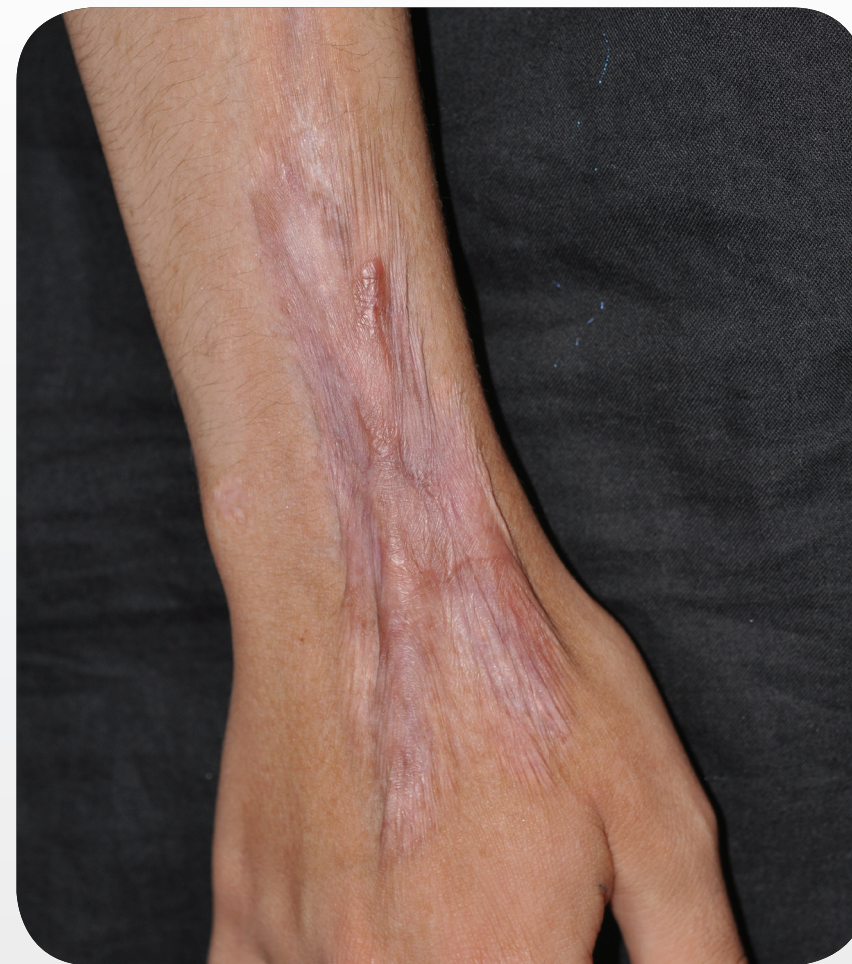Courtesy of Max Murison, MD

PB-1003880 Rev C

# Scar Revision



Baseline

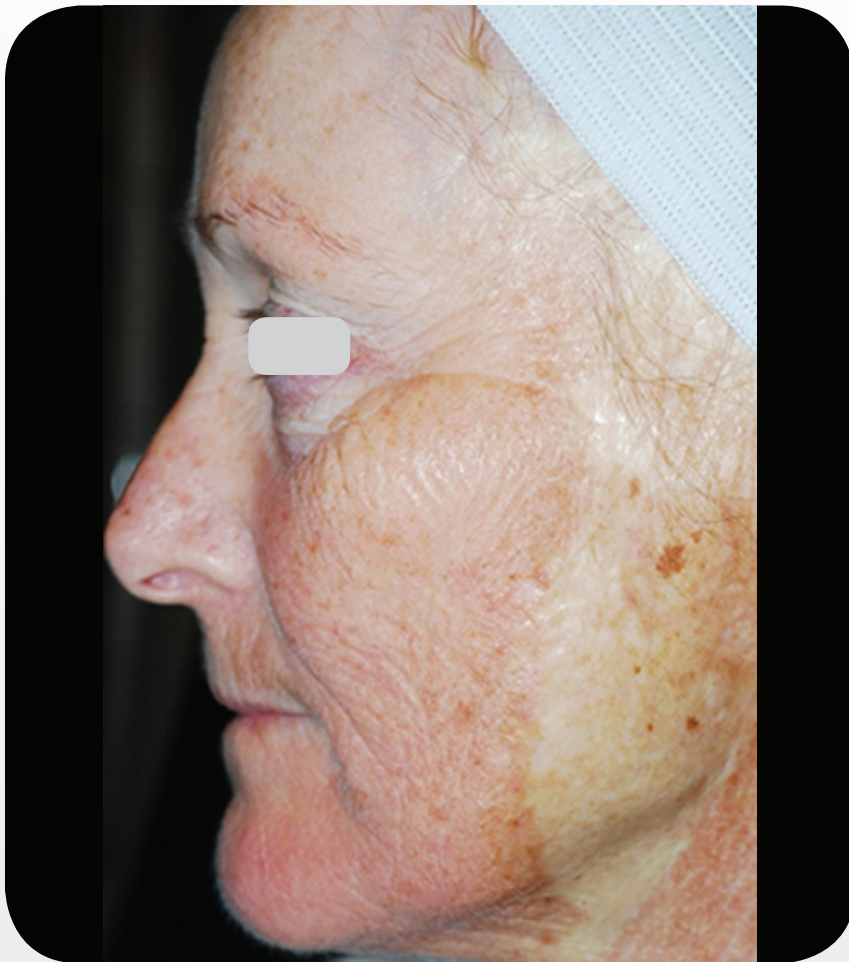

2 years after treatment

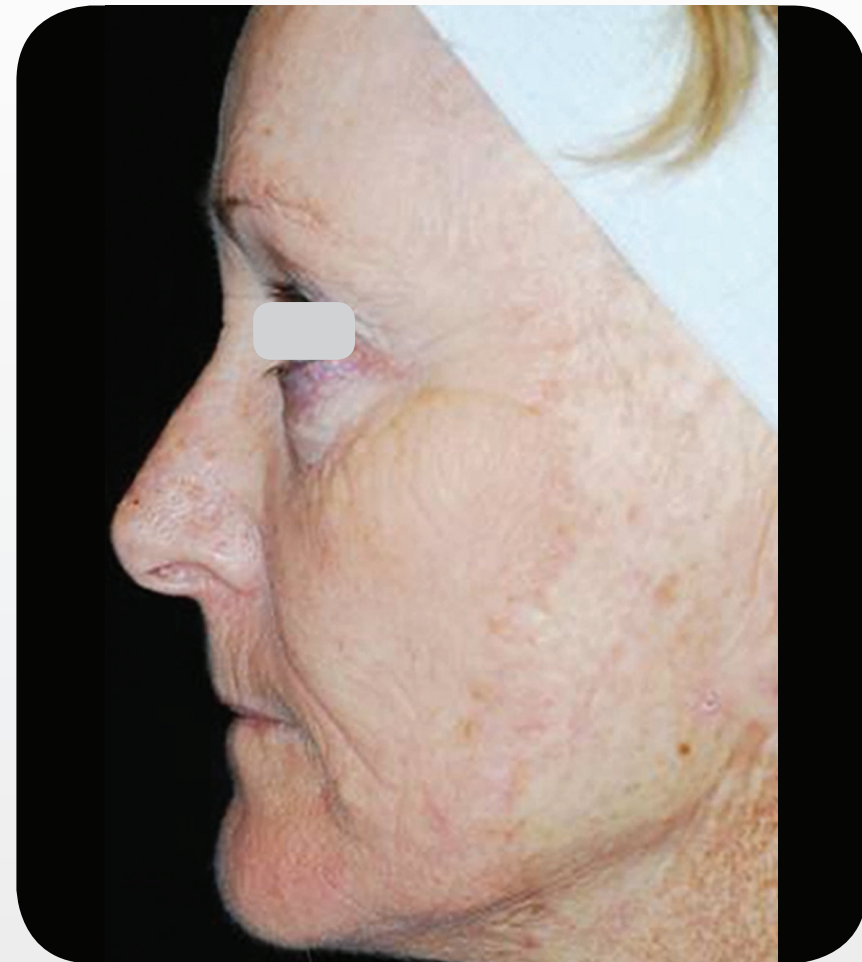Courtesy of Jill S. Waibel, MD

PB-1003880 Rev C

# Scar Revision



Baseline

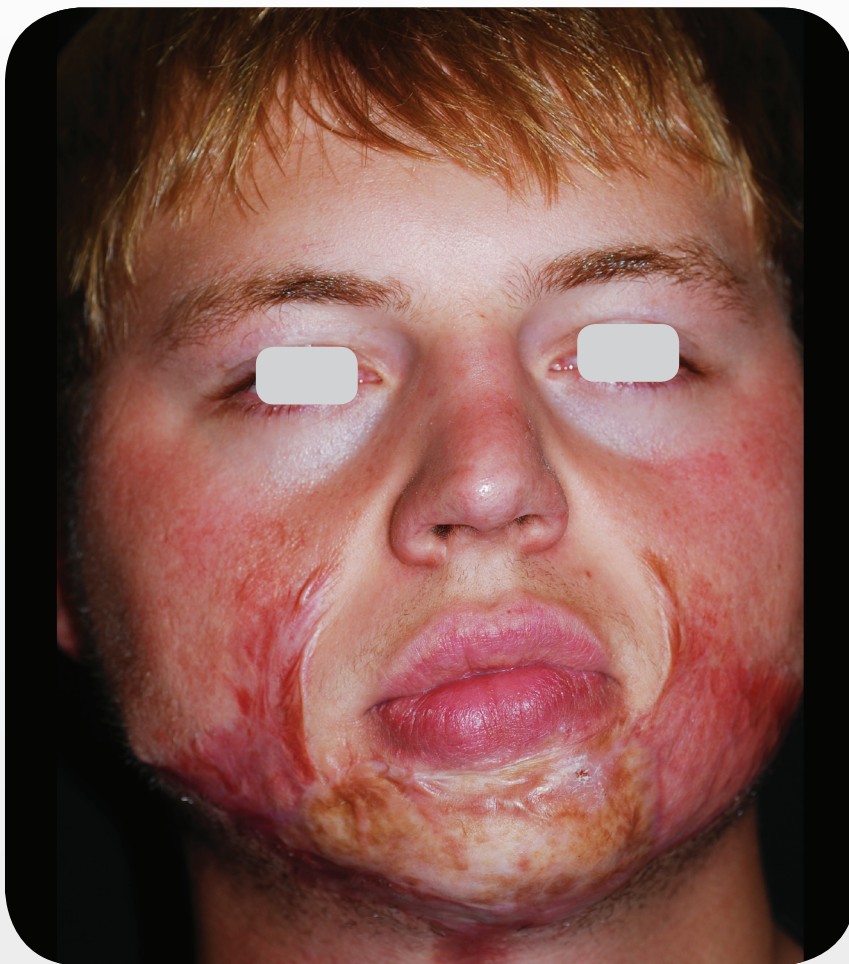

After treatment

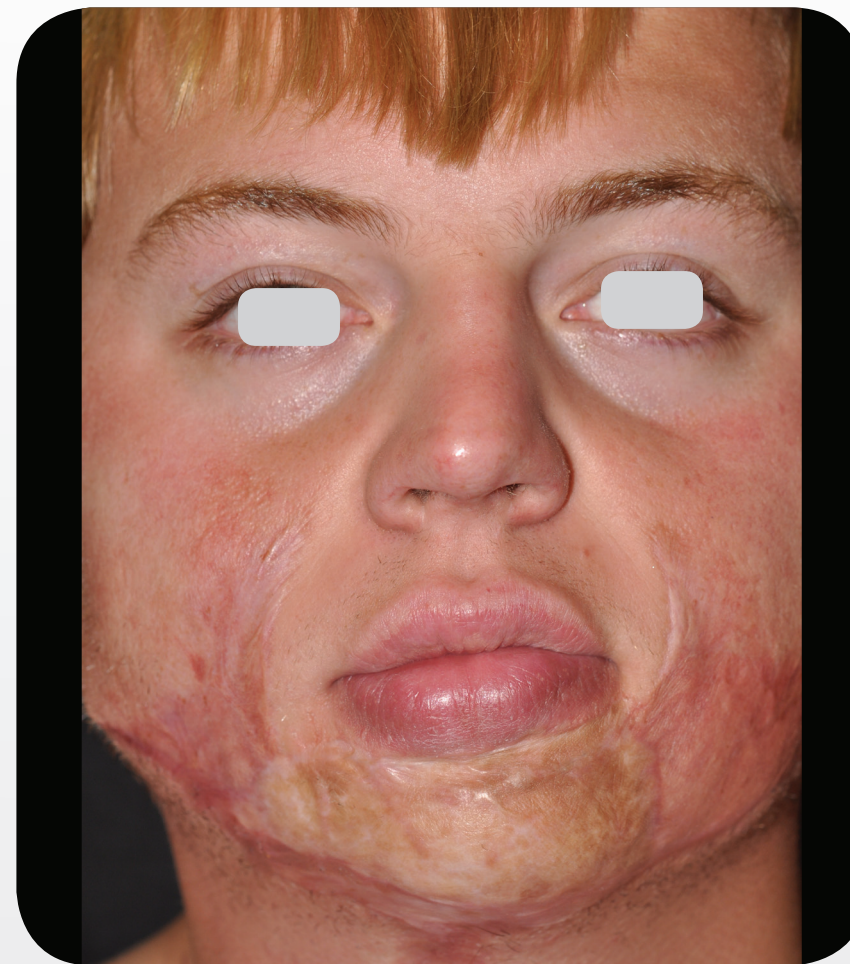
Courtesy of Jill S. Waibel, MD

PB-1003880 Rev C

# Scar Revision



Baseline

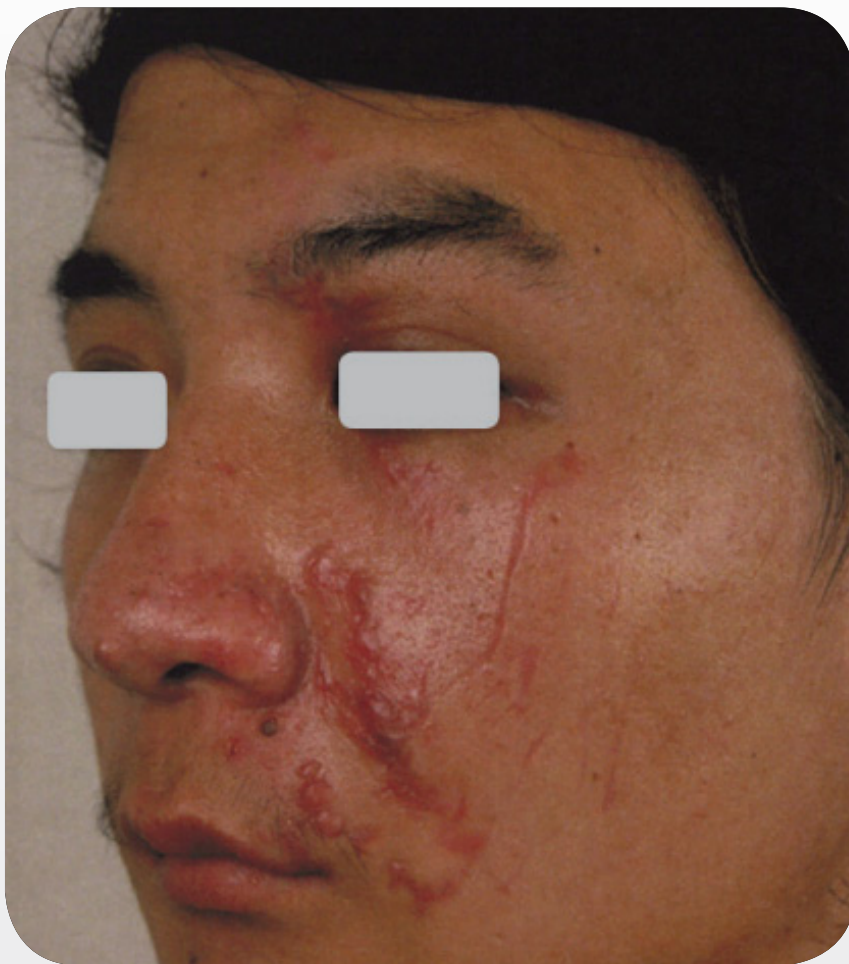

After treatment

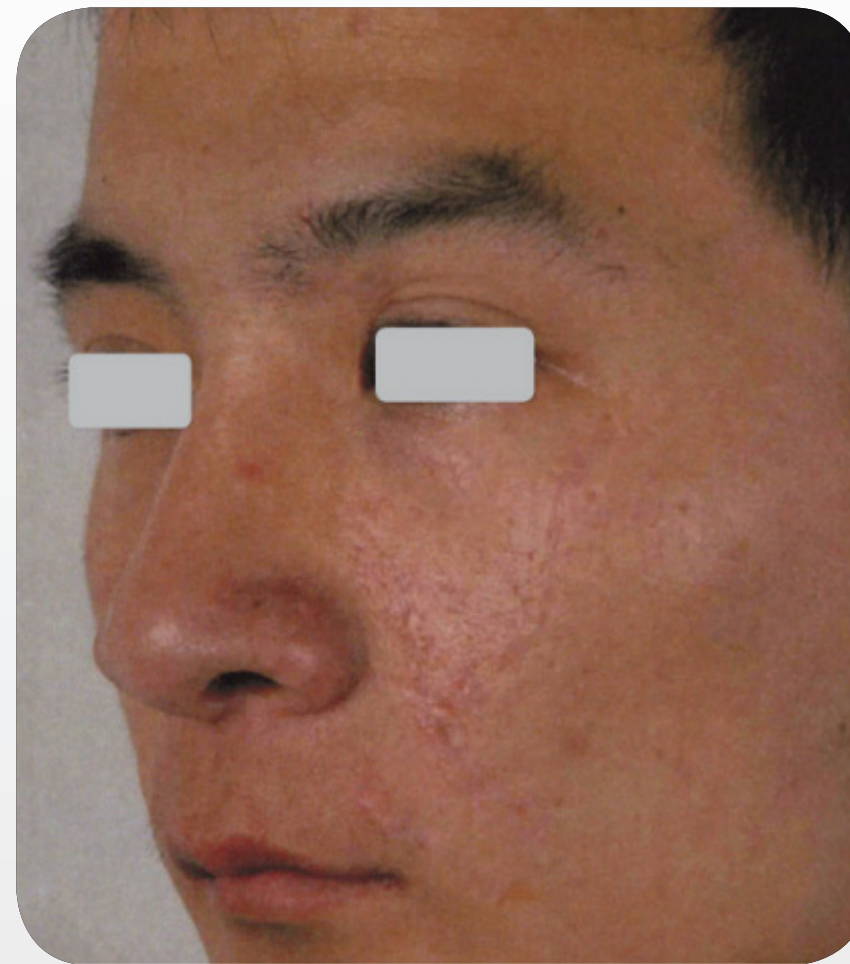Courtesy of Jill S. Waibel, MD

PB-1003880 Rev C

# Scar Revision combined with PDL



Baseline

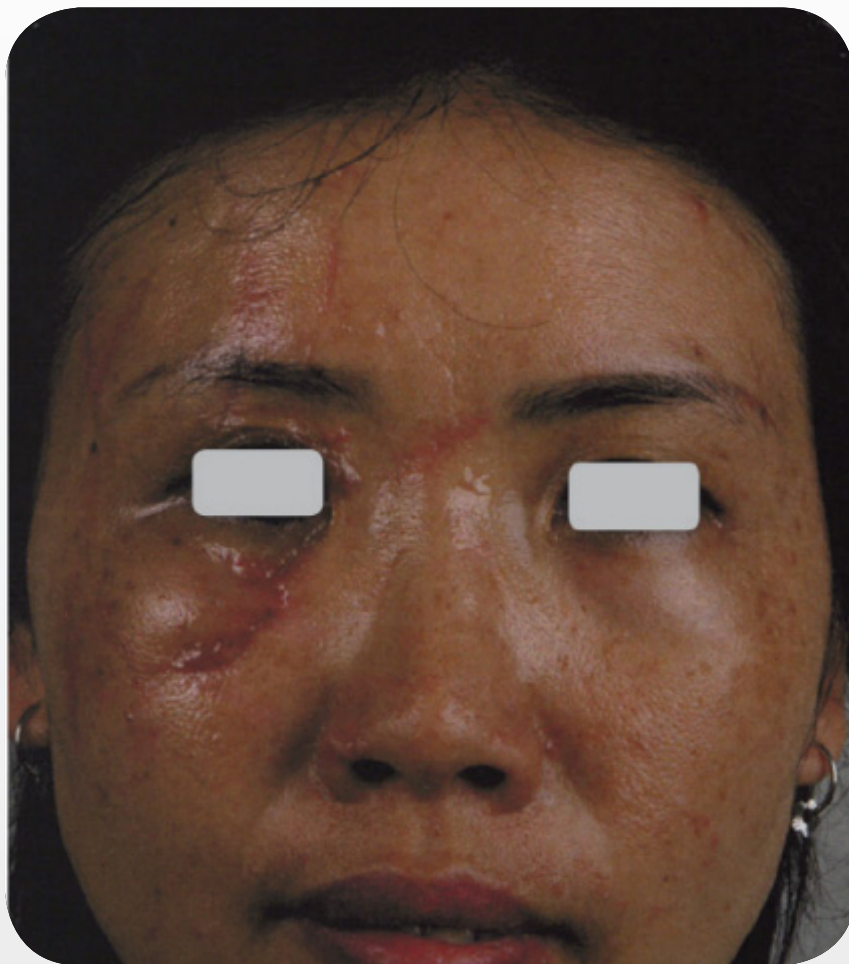

After treatment

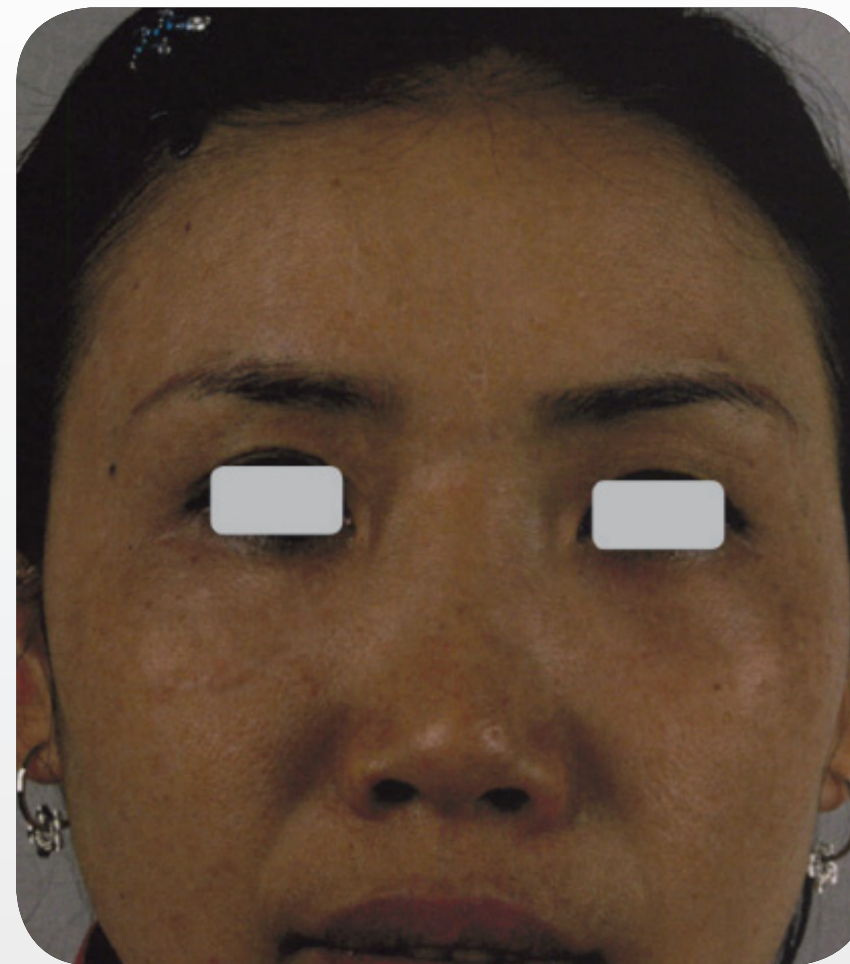
Courtesy of Tan Jun, MD

PB-1003880 Rev C

# Scar Revision combined with PDL



Baseline

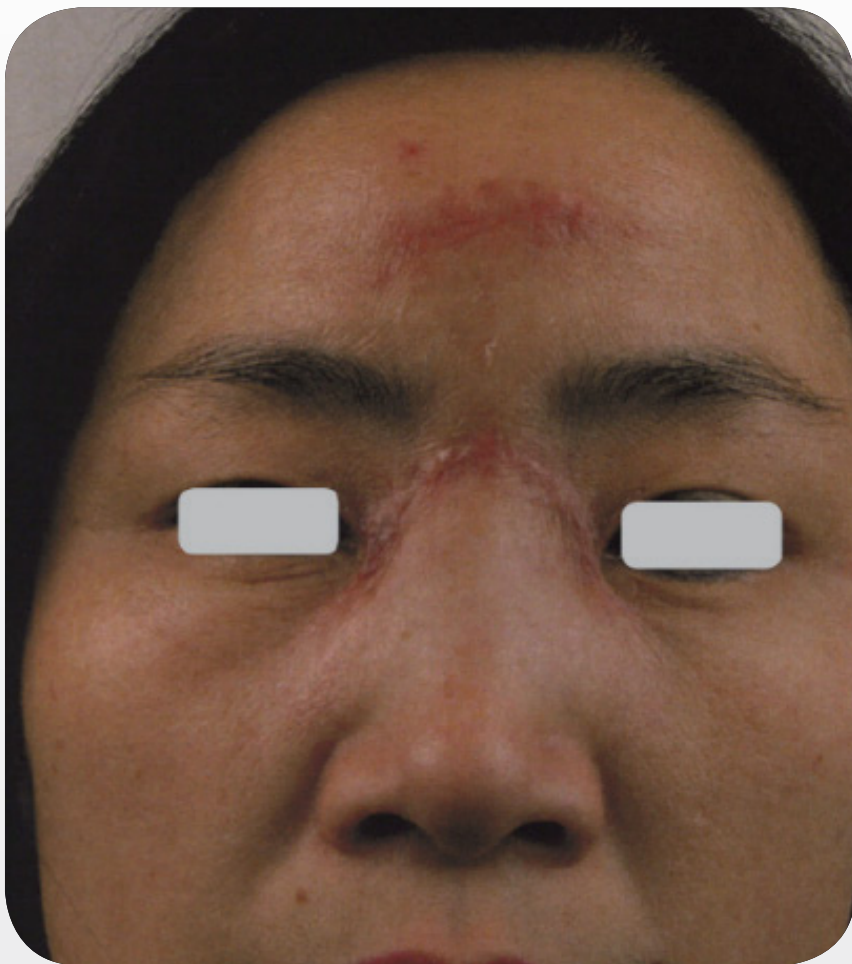


After treatment

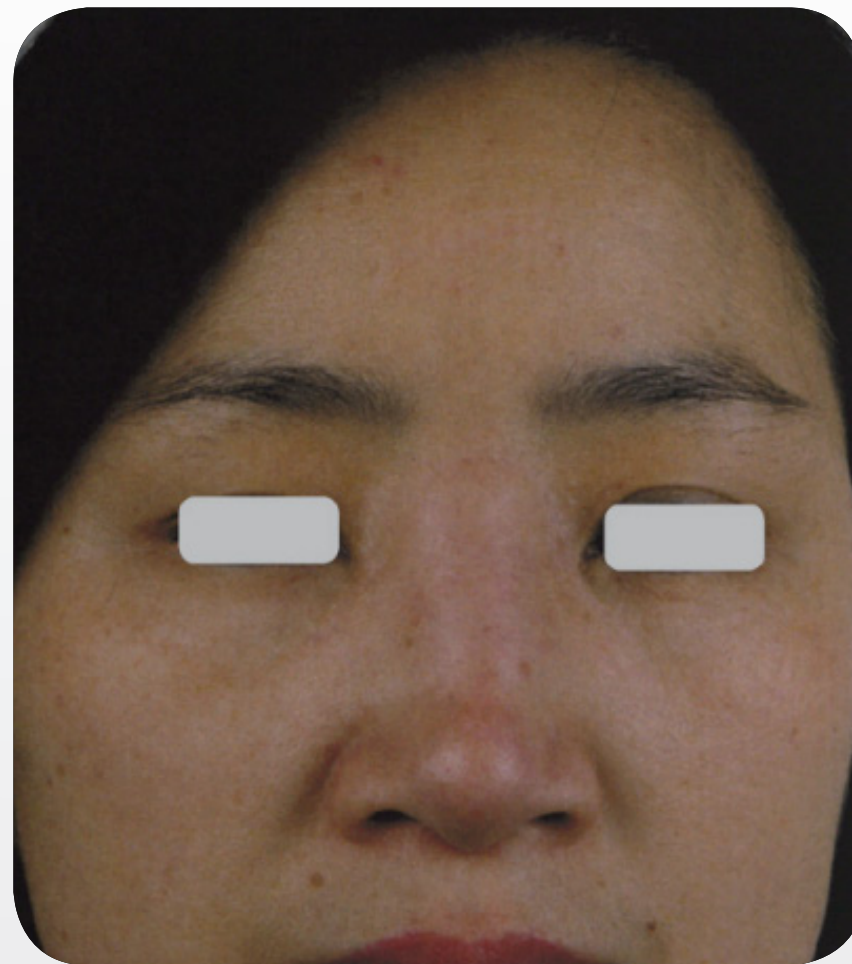
Courtesy of Tan Jun, MD

PB-1003880 Rev C

# Scar Revision combined with PDL



Baseline



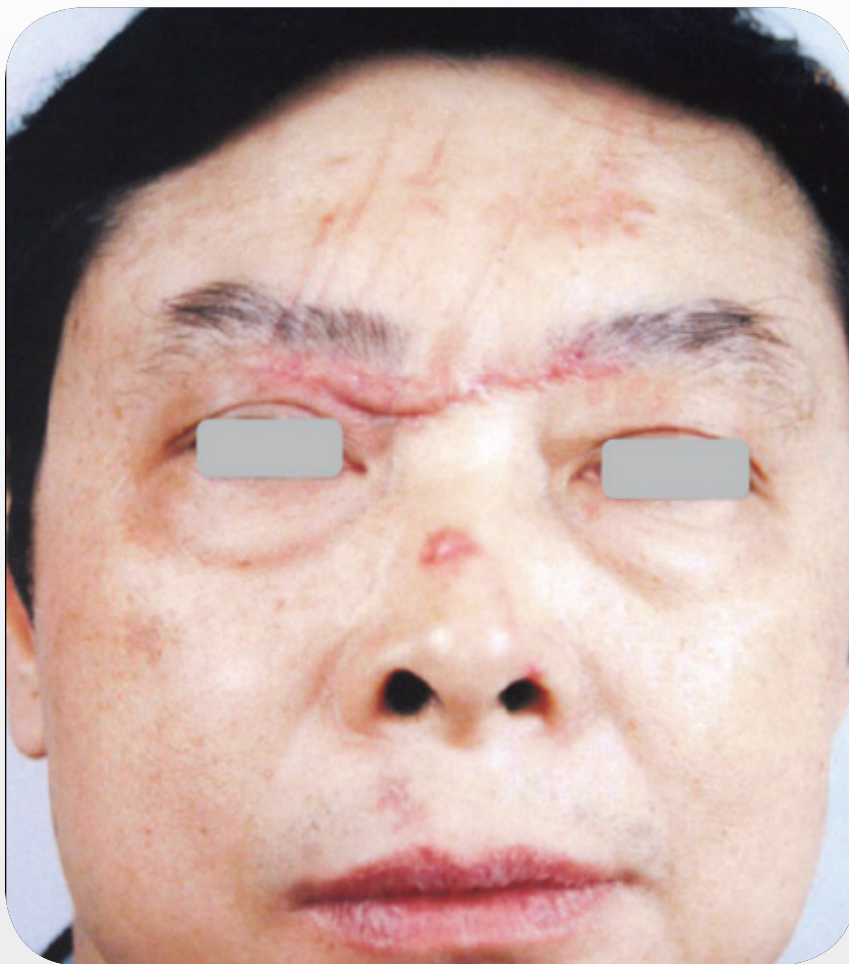After treatment

Courtesy of Tan Jun, MD

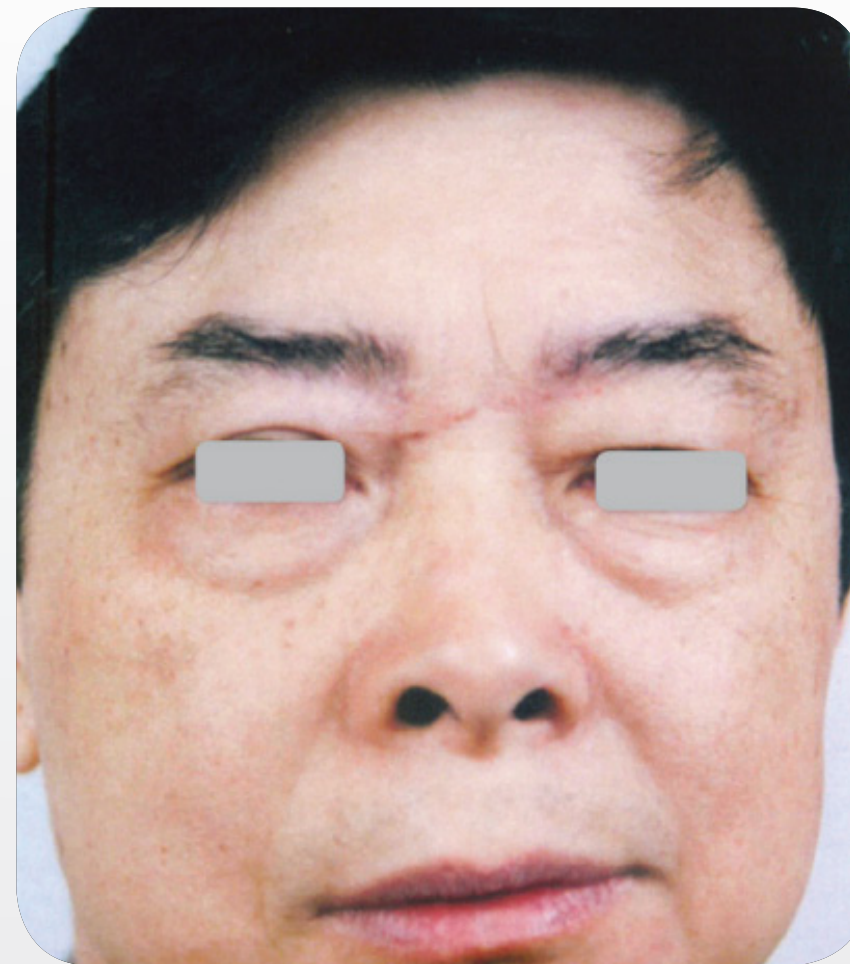PB-1003880 Rev C



# Scar Revision combined with VPW532



Baseline

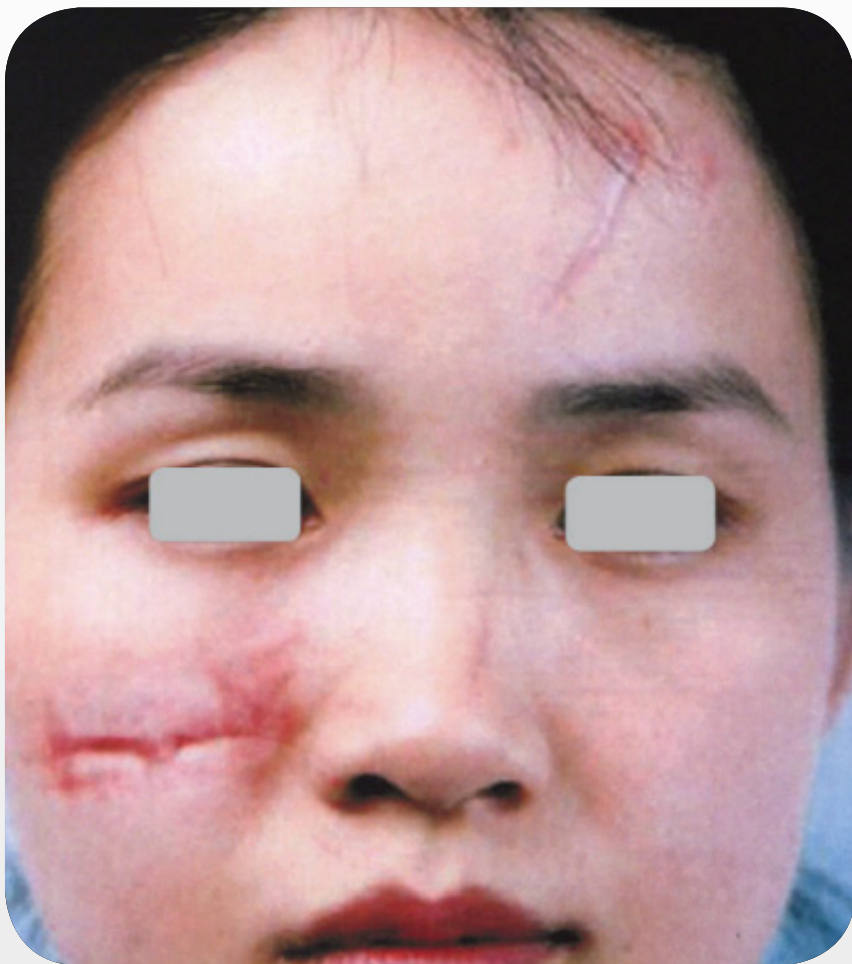

After treatment

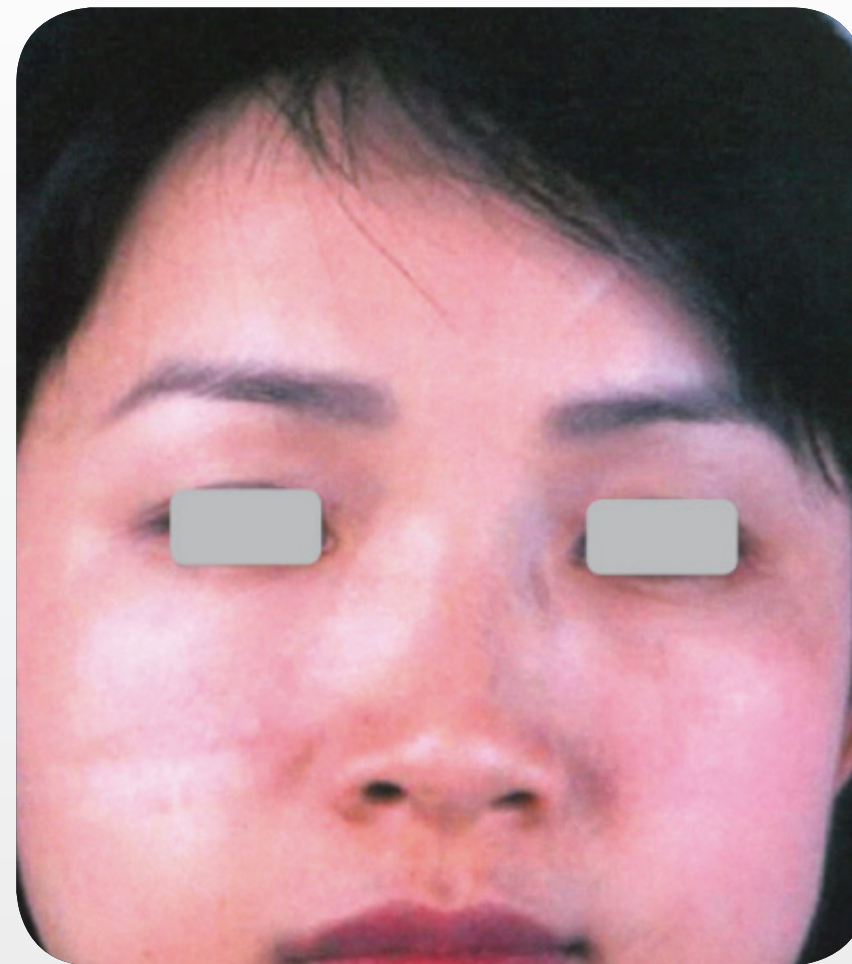Courtesy of Tan Jun, MD

PB-1003880 Rev C

# Scar Revision combined with PDL



Baseline

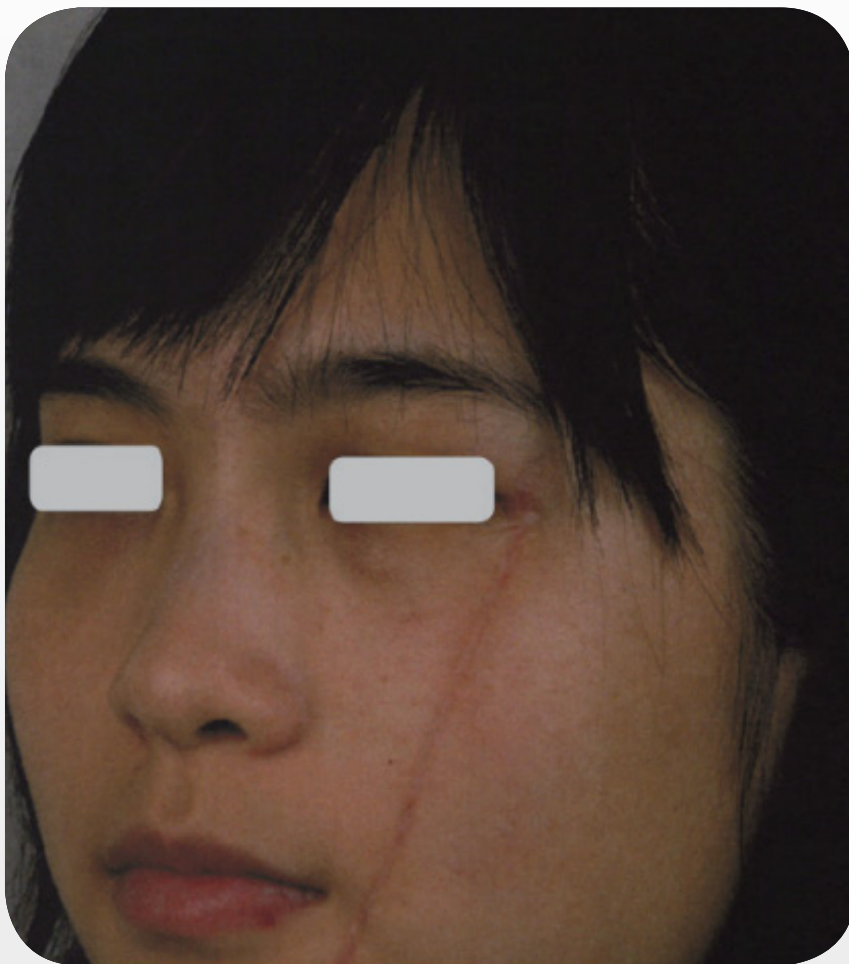


After treatment

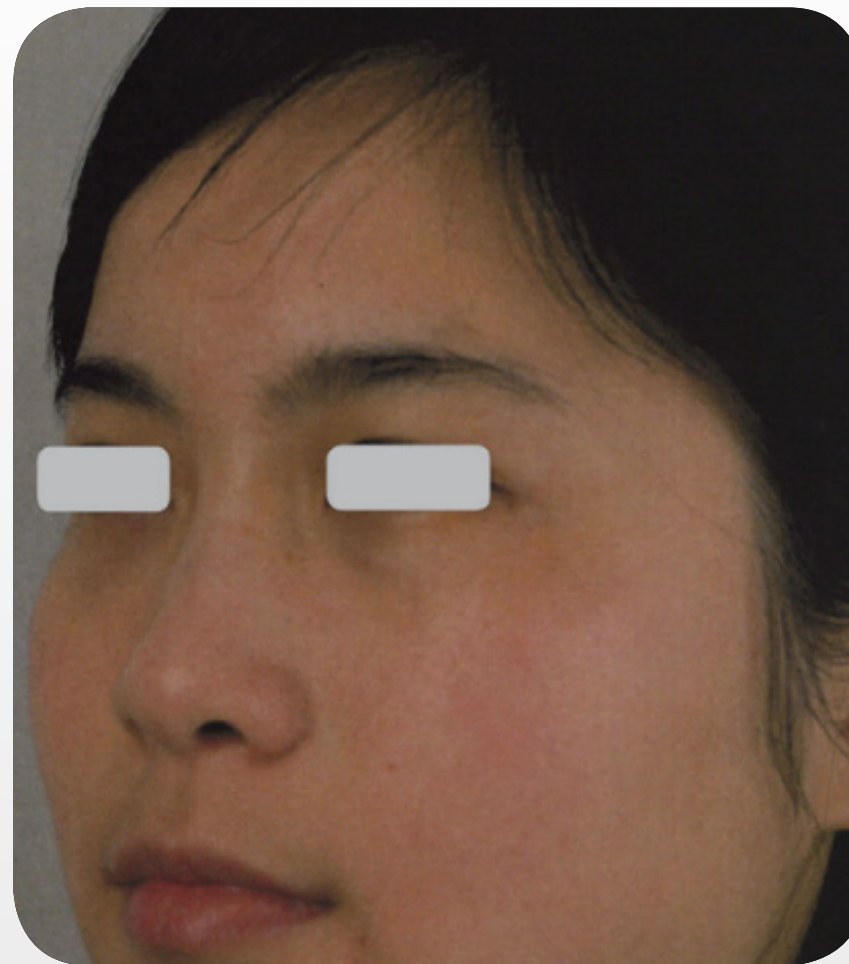Courtesy of Tan Jun, MD

PB-1003880 Rev C

# Scar Revision combined with PDL



Baseline

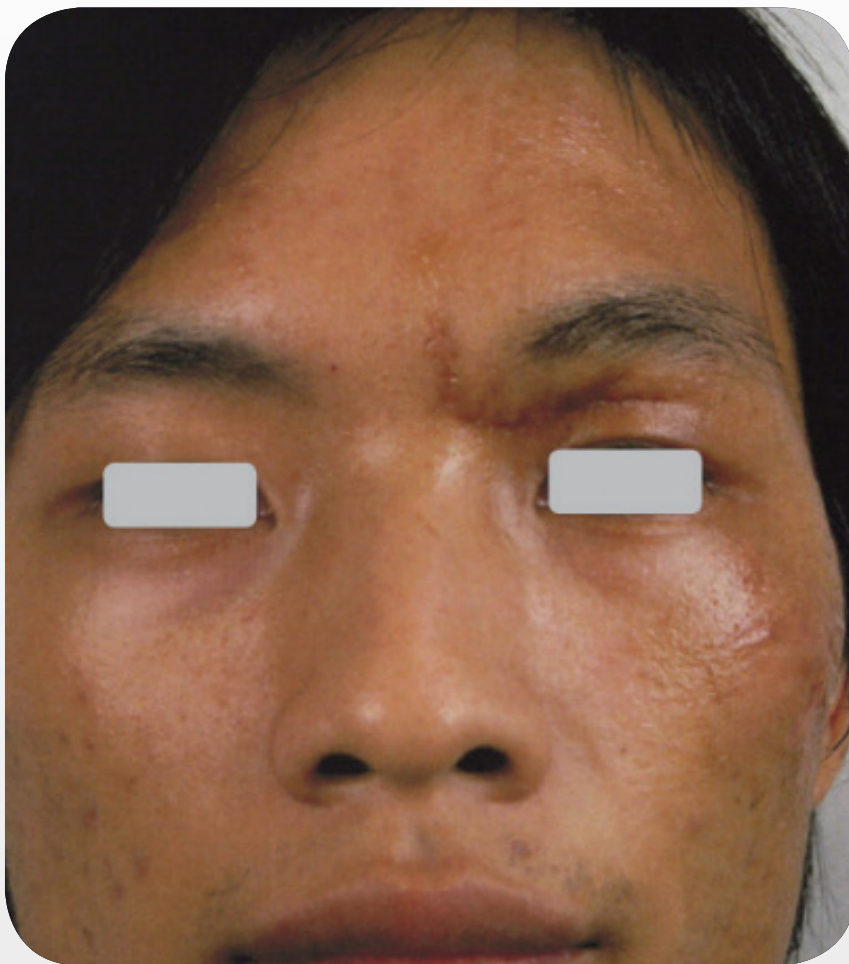

After treatment

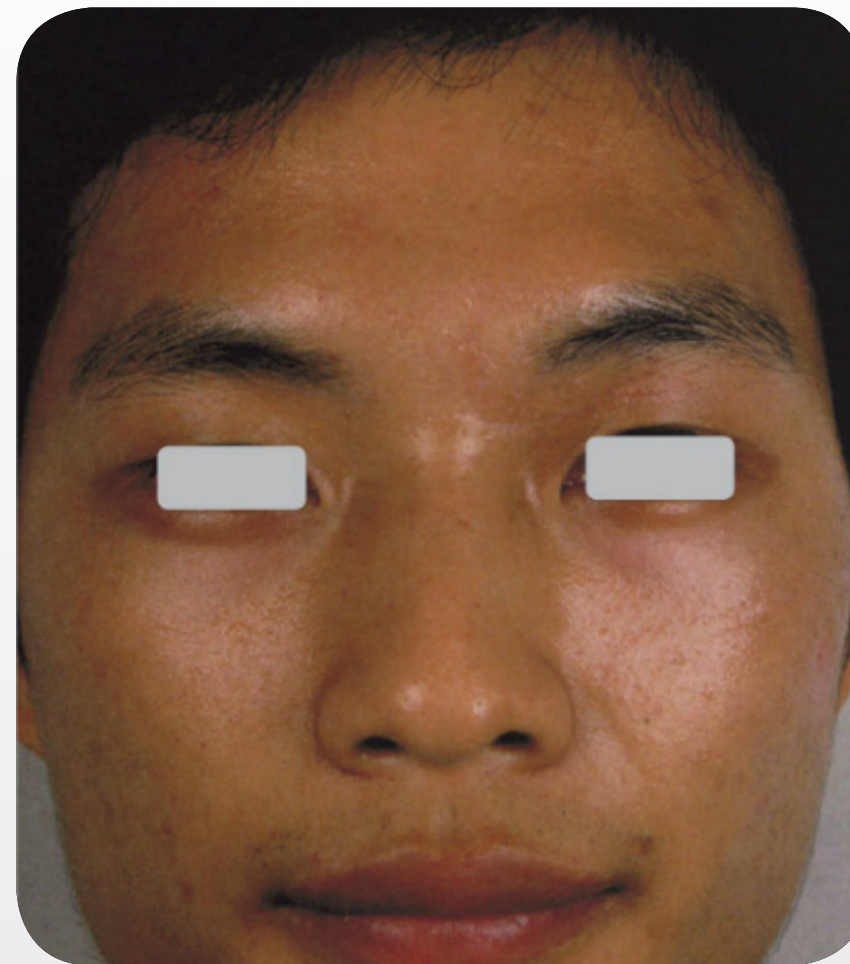
Courtesy of Tan Jun, MD

PB-1003880 Rev C

# Scar Revision combined with PDL



Baseline

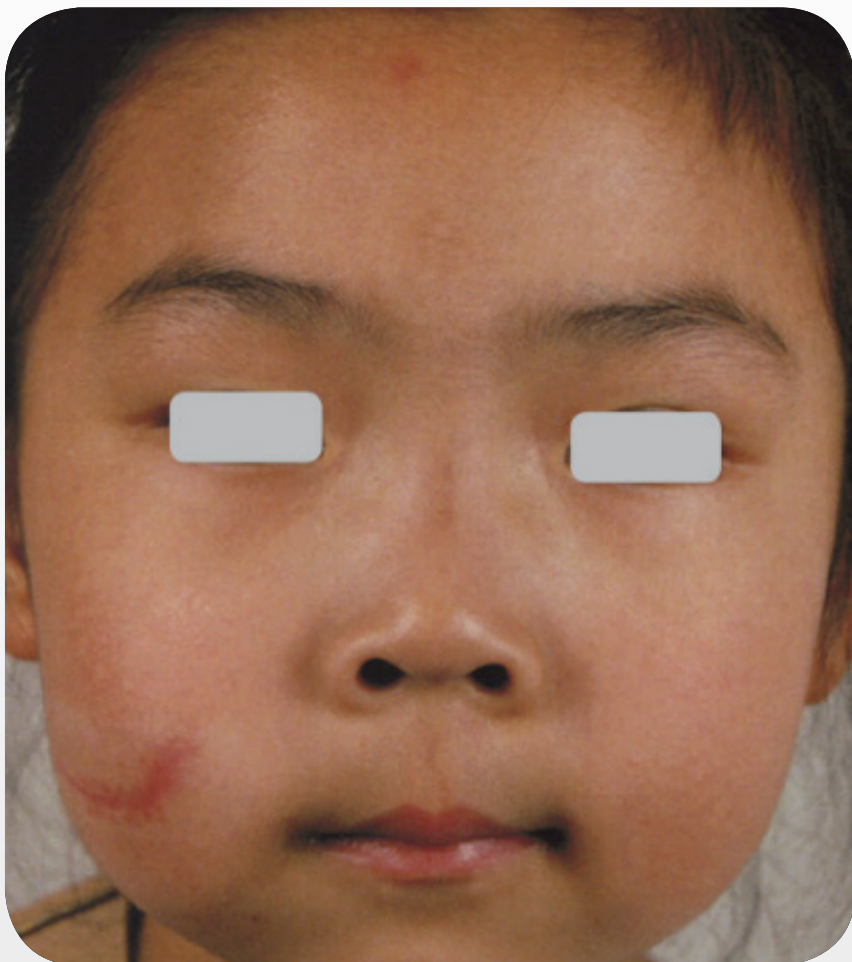

After treatment

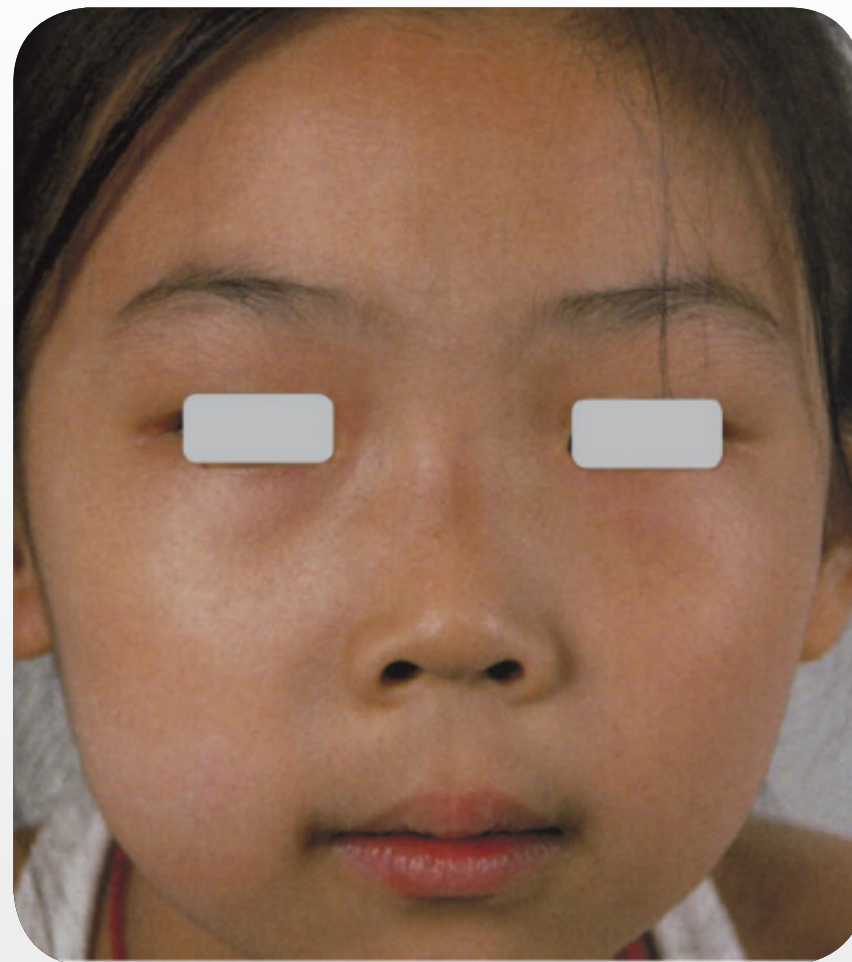
Courtesy of Tan Jun, MD

PB-1003880 Rev C

# Scar Revision combined with PDL



Baseline

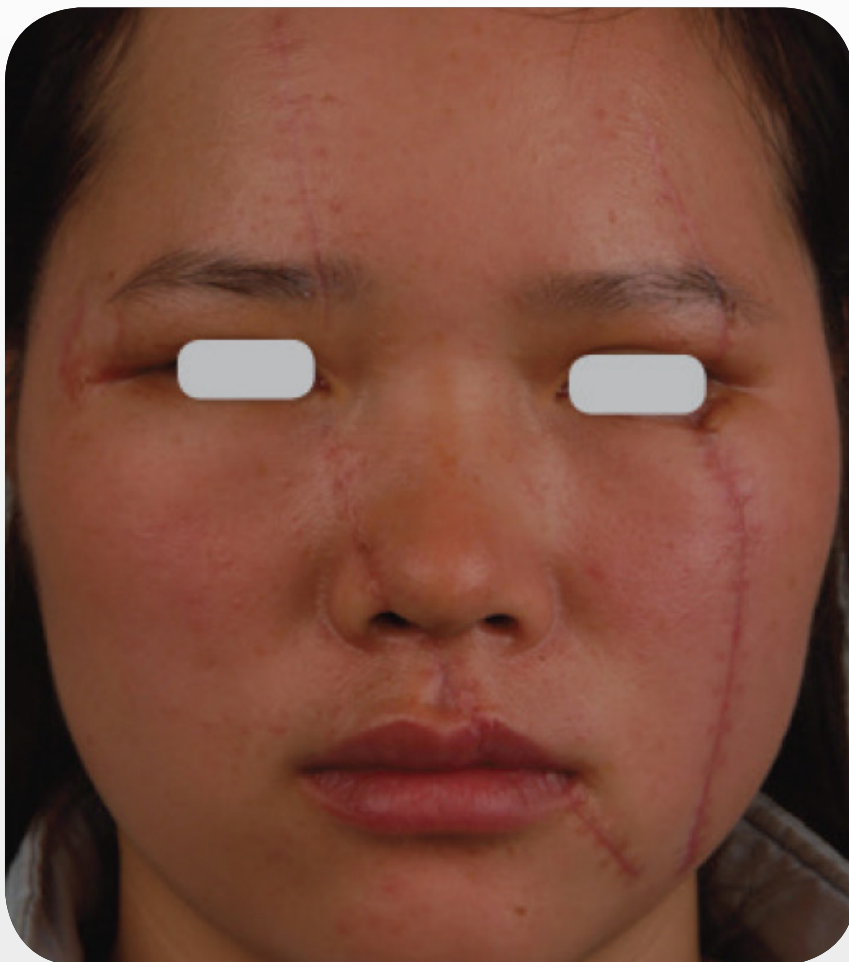

After treatment

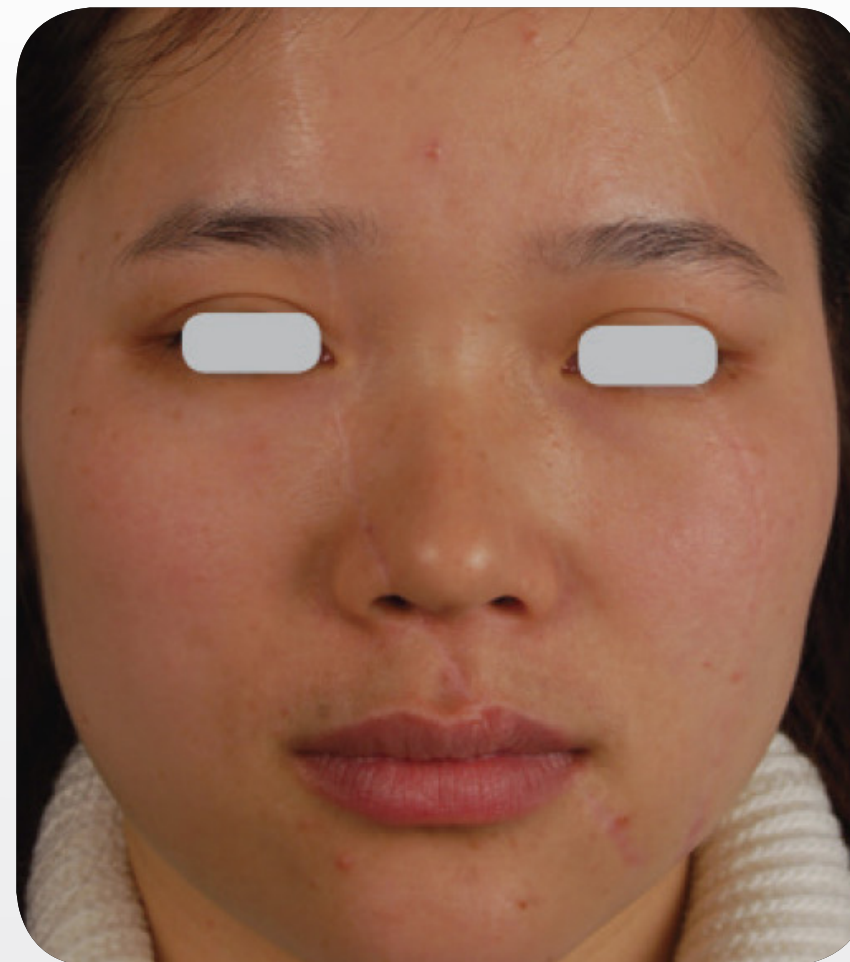
Courtesy of Tan Jun, MD

PB-1003880 Rev C

# Scar Revision combined with VPW532



Baseline

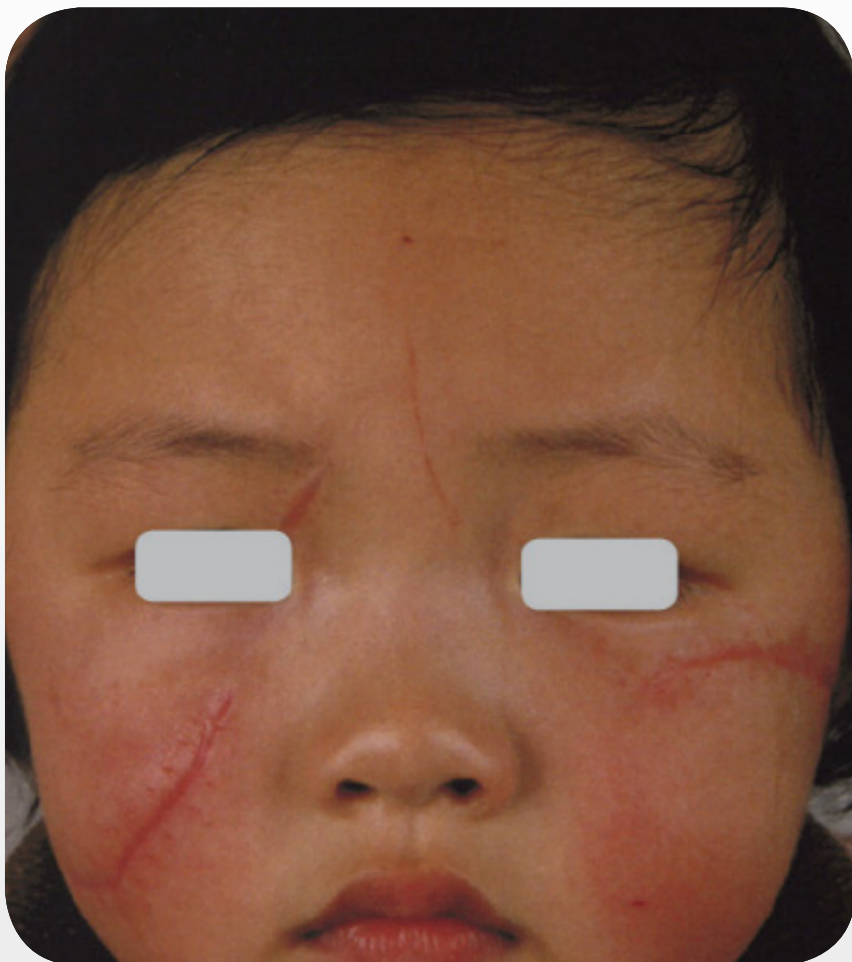

After treatment

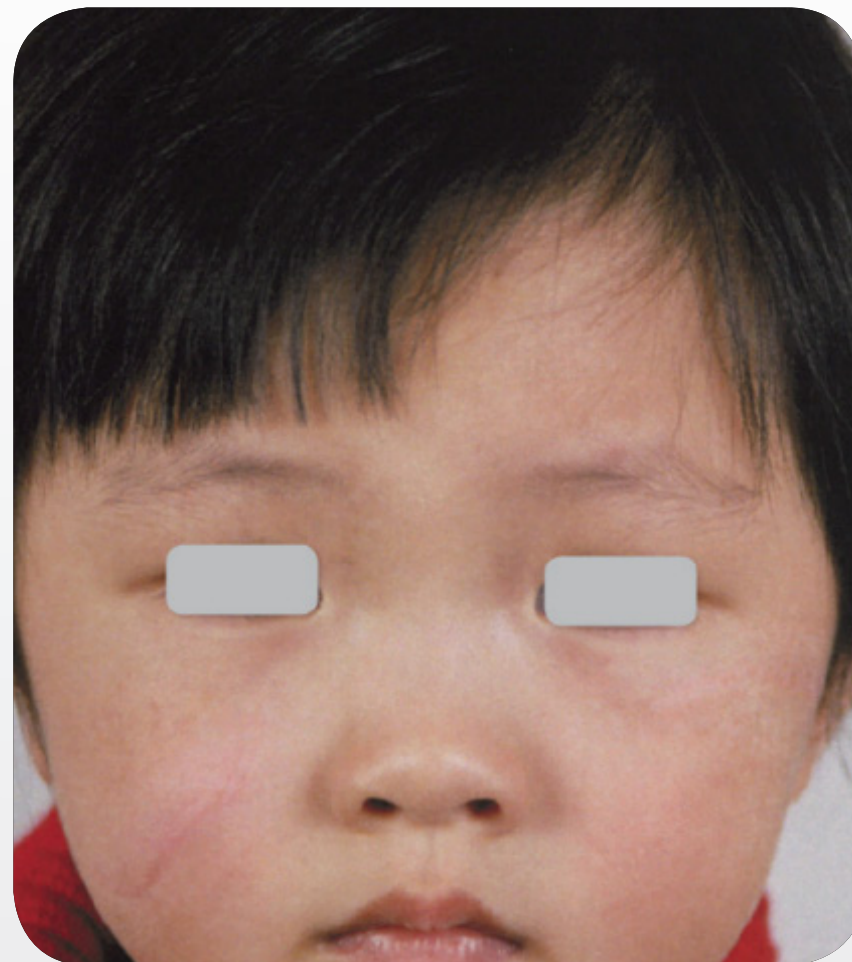Courtesy of Tan Jun, MD

PB-1003880 Rev C

# Scar Revision combined with PDL



Baseline

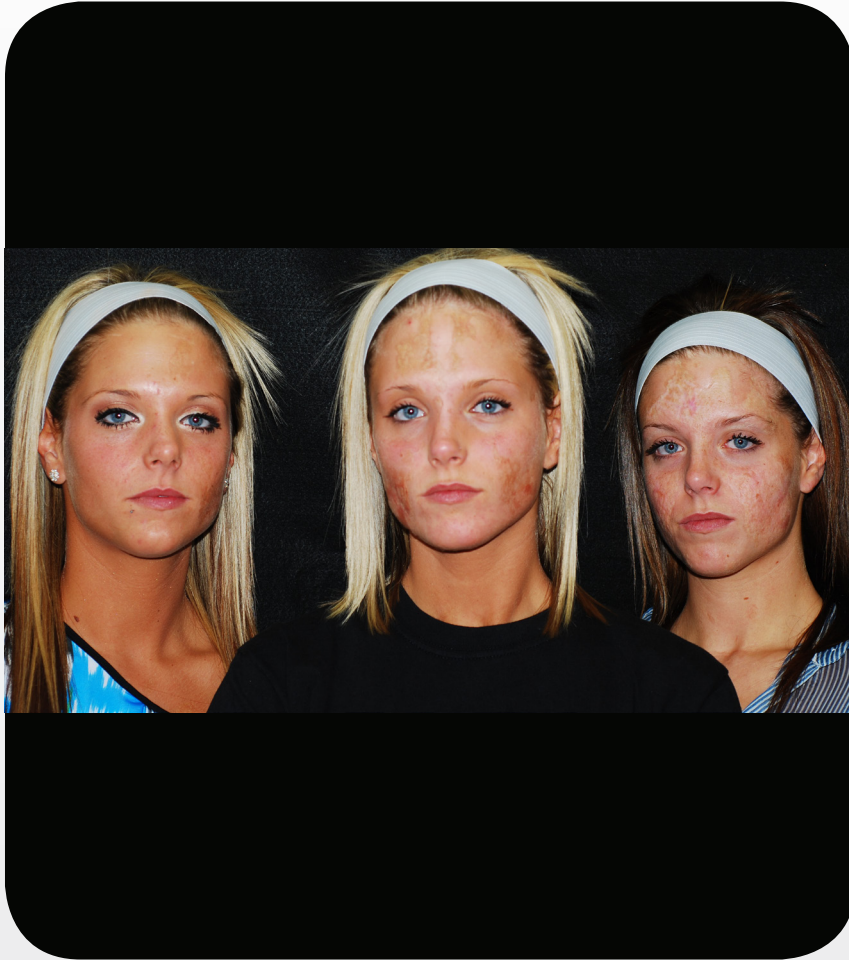

After treatment

Courtesy of Tan Jun, MD

PB-1003880 Rev C

# Scar Revision The Berns Triplets; Chandra, Trae & Jordan



Baseline



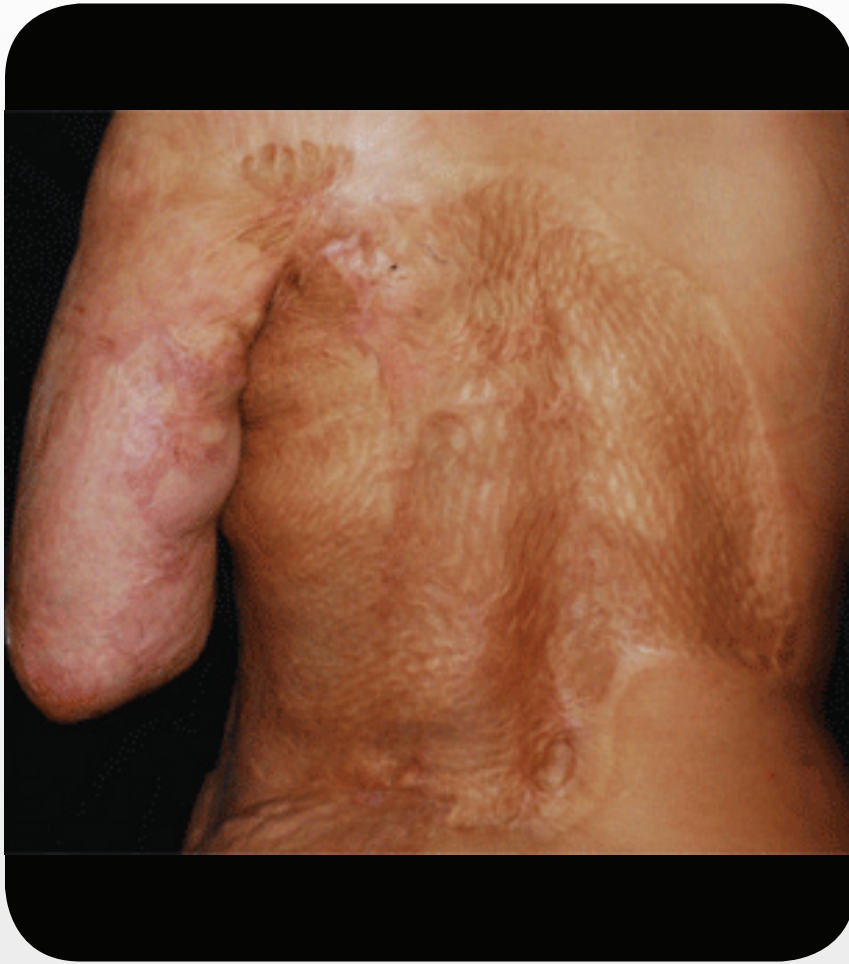
After treatment

Courtesy of Jill S. Waibel, MD

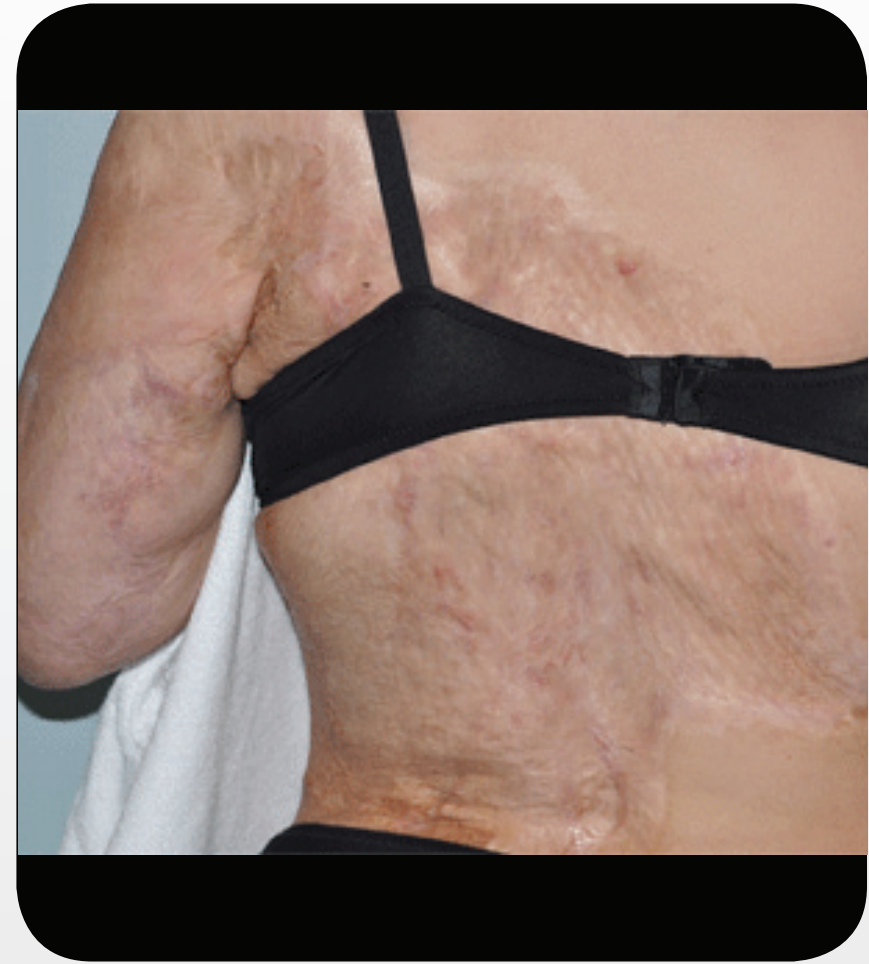PB-1003880 Rev C



# Scar Revision The Berns Triplets; Chandra, Trae & Jordan



Baseline

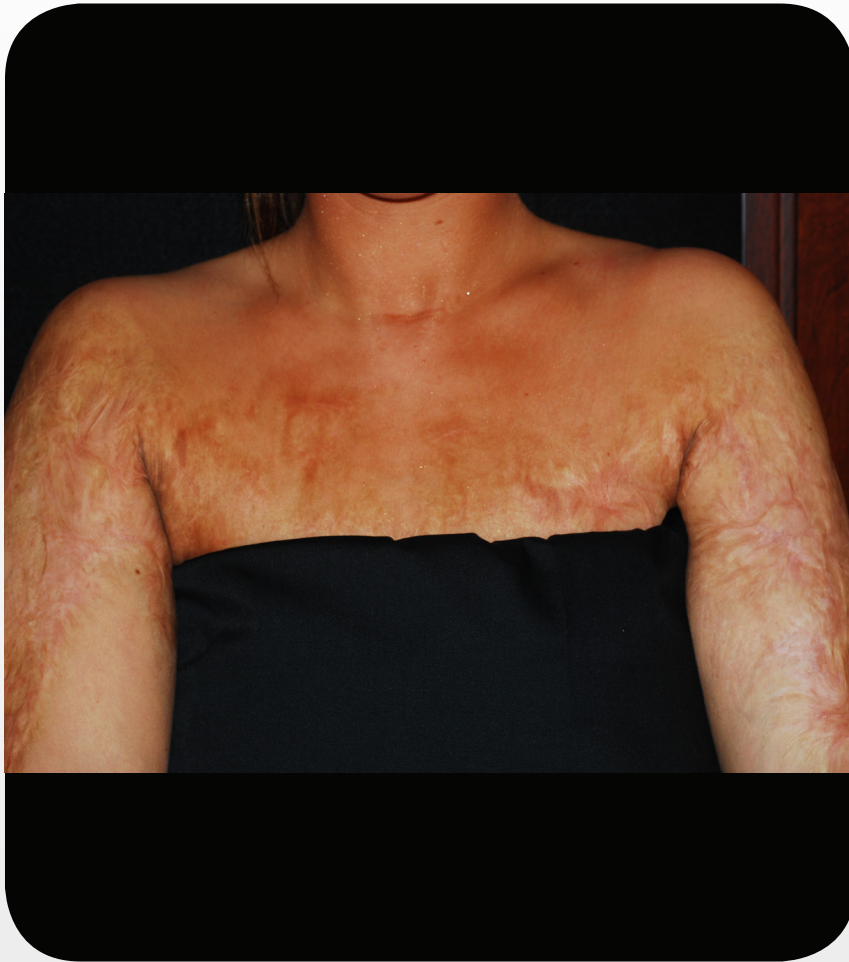

After treatment

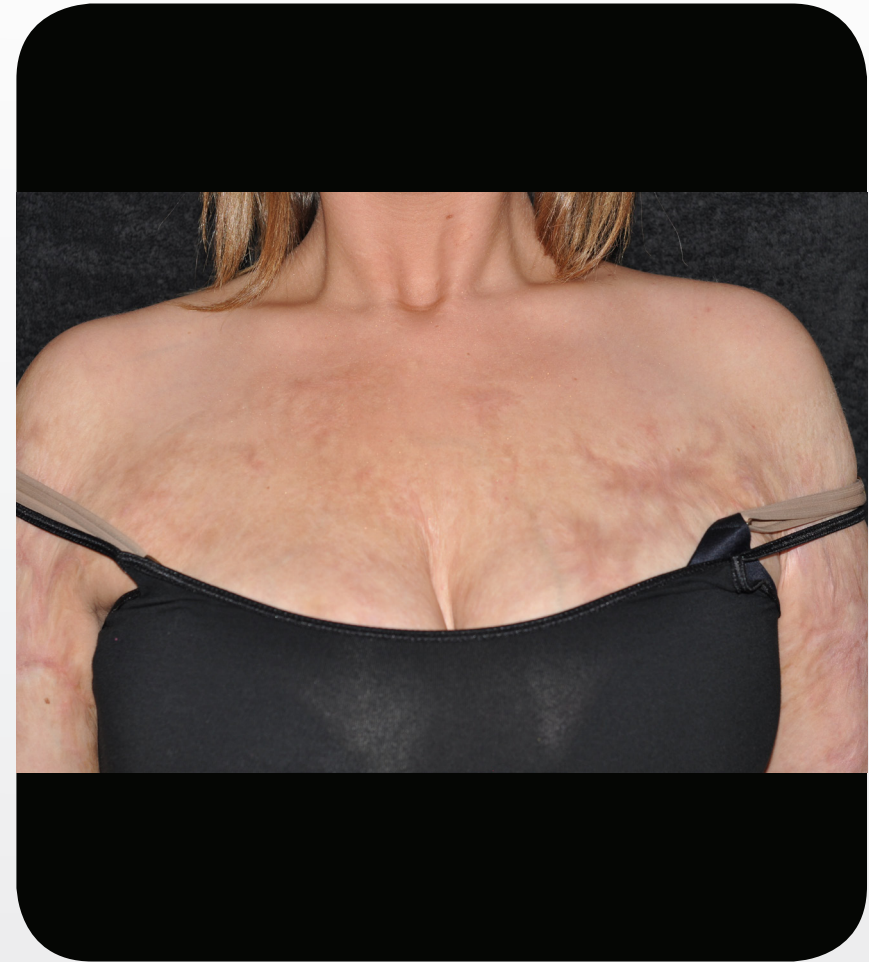Courtesy of Jill S. Waibel, MD

PB-1003880 Rev C

# Scar Revision The Berns Triplets; Chandra, Trae & Jordan



Baseline

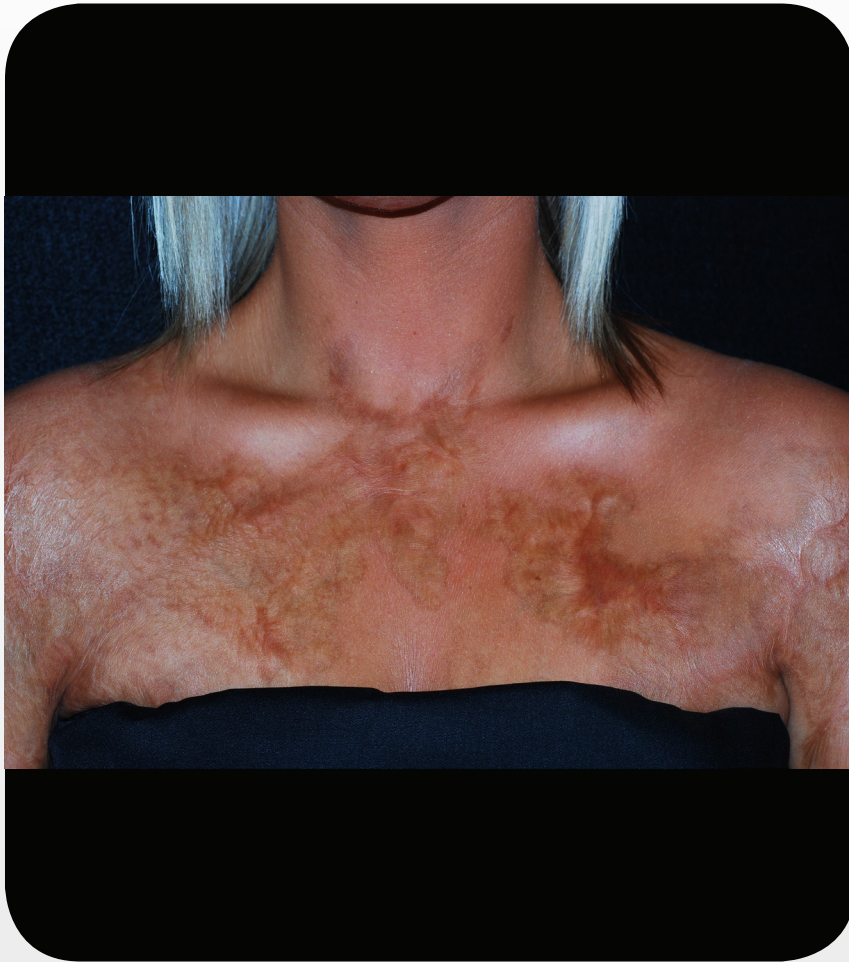

After treatment

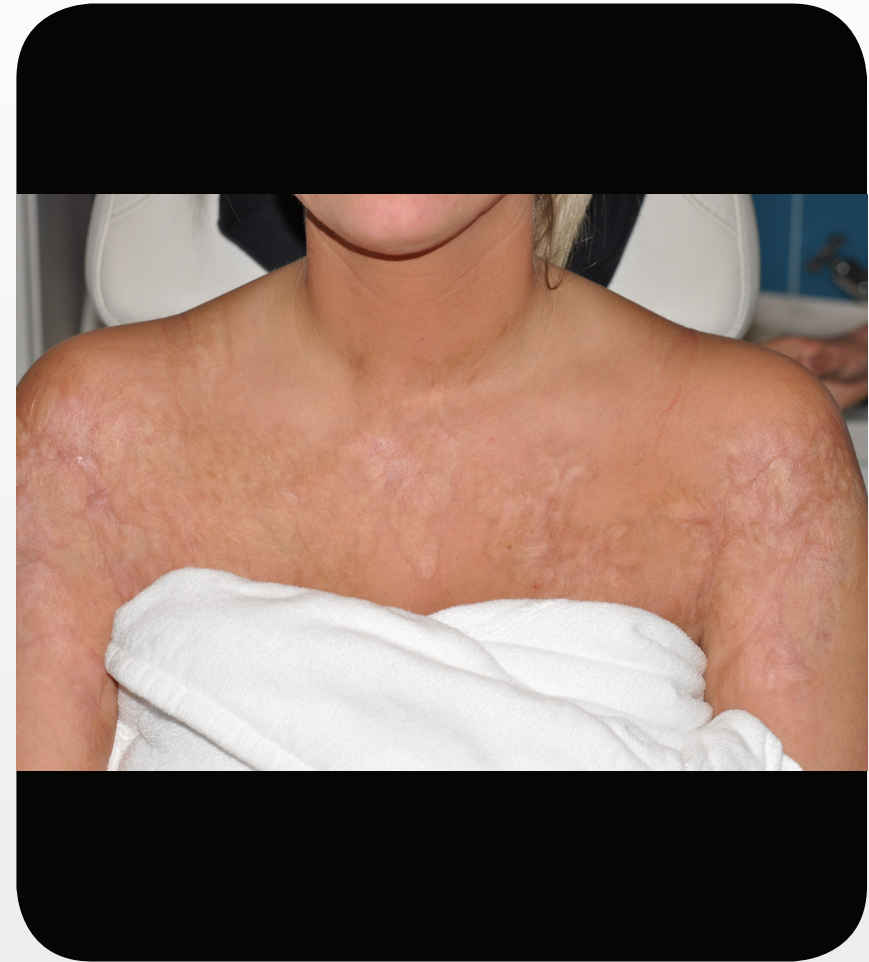Courtesy of Jill S. Waibel, MD

PB-1003880 Rev C

# Scar Revision The Berns Triplets; Chandra, Trae & Jordan



Baseline

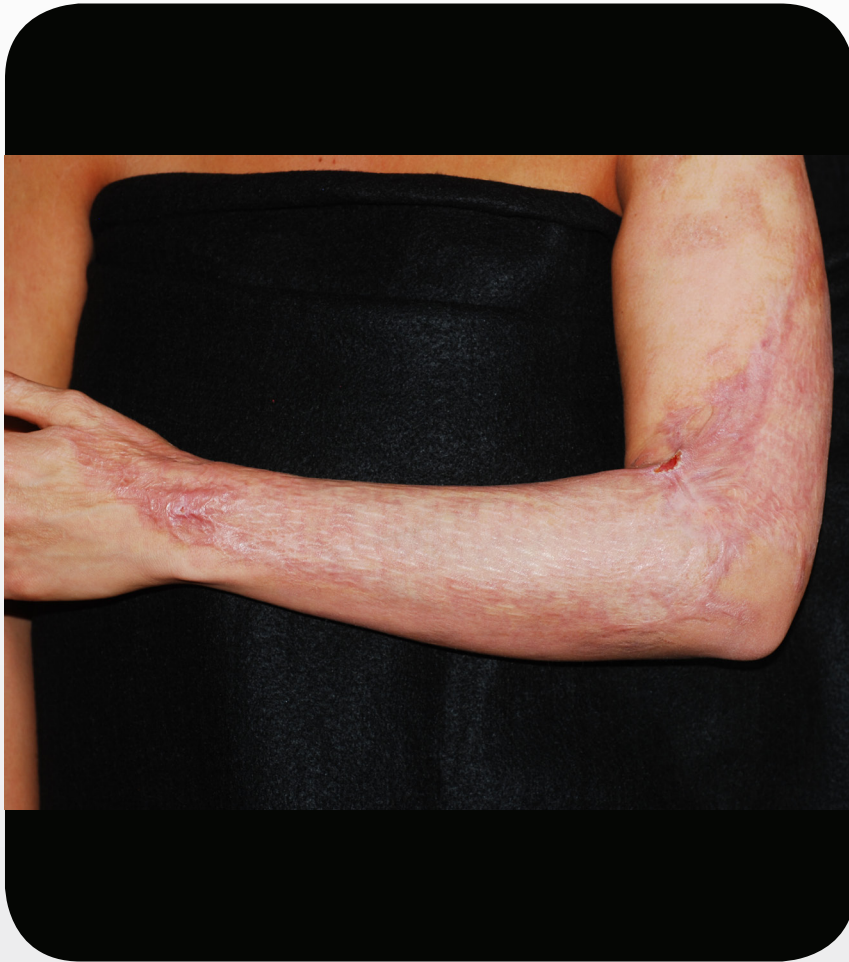

After treatment

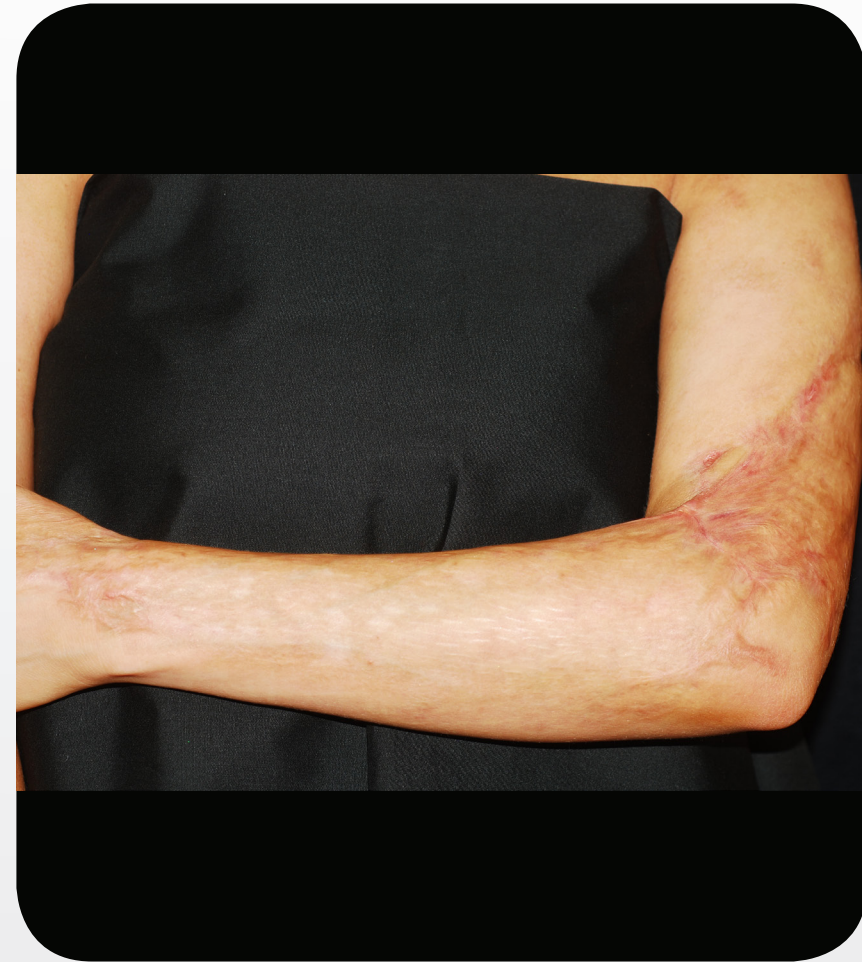Courtesy of Jill S. Waibel, MD

PB-1003880 Rev C

# Scar Revision The Berns Triplets; Chandra, Trae & Jordan



Baseline

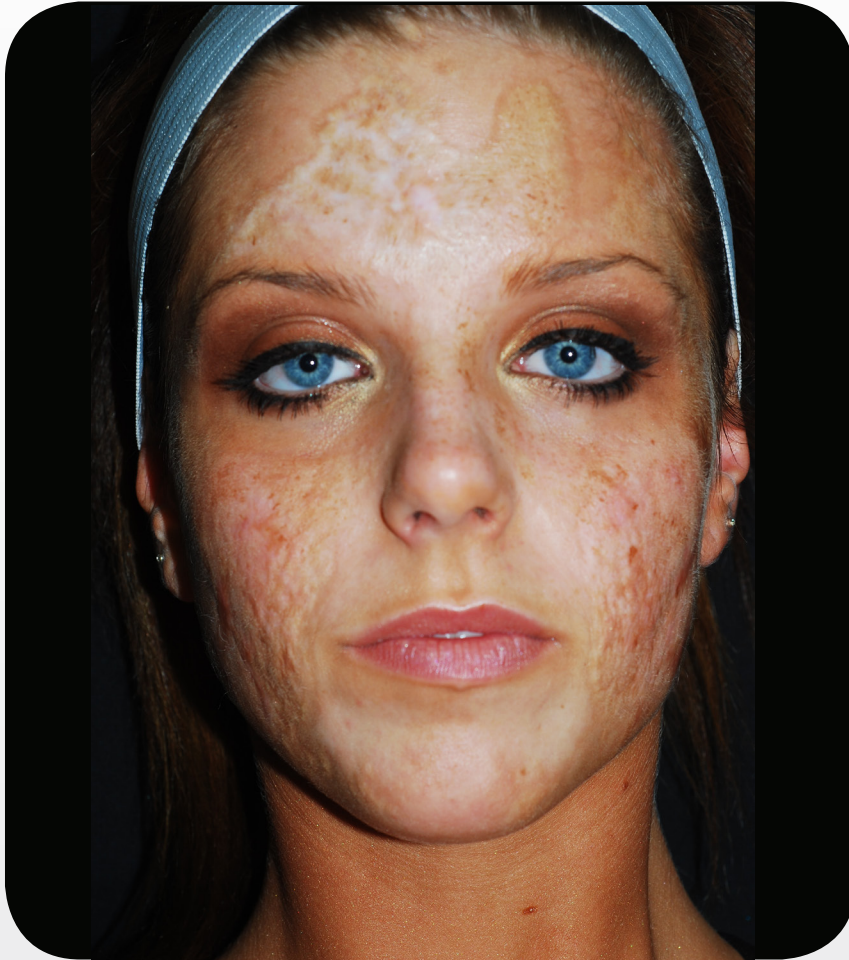

After treatment

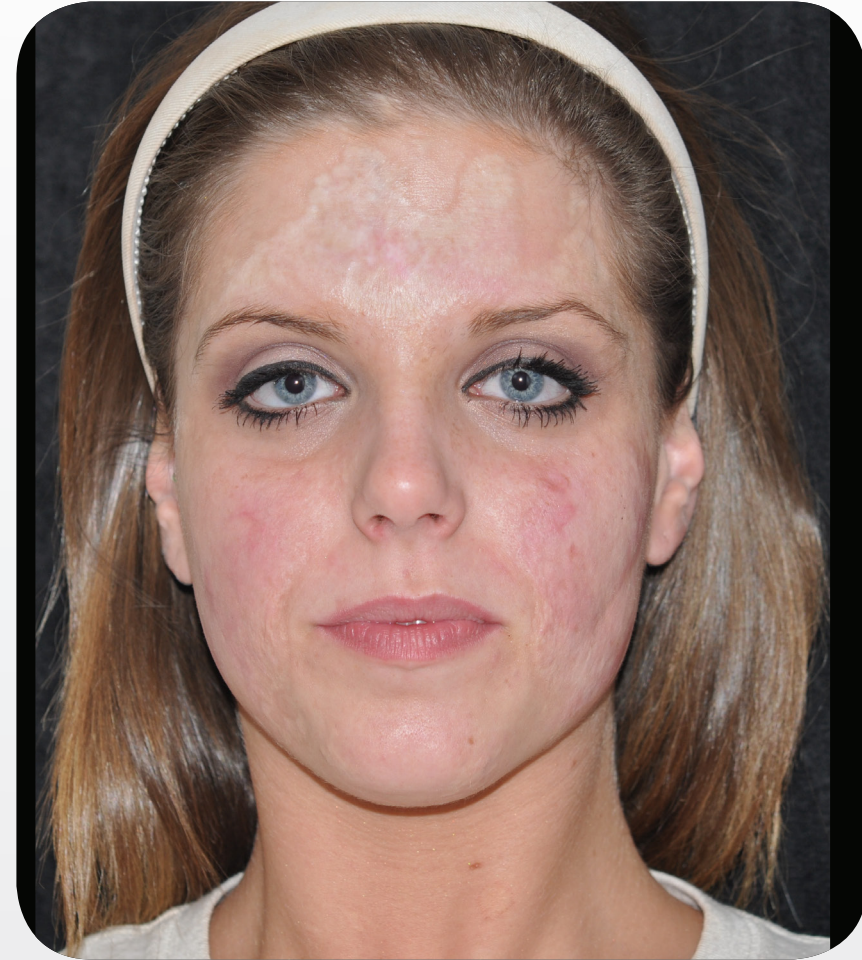Courtesy of Jill S. Waibel, MD

PB-1003880 Rev C

# Scar Revision The Berns Triplets; Chandra, Trae & Jordan



Baseline




After treatment

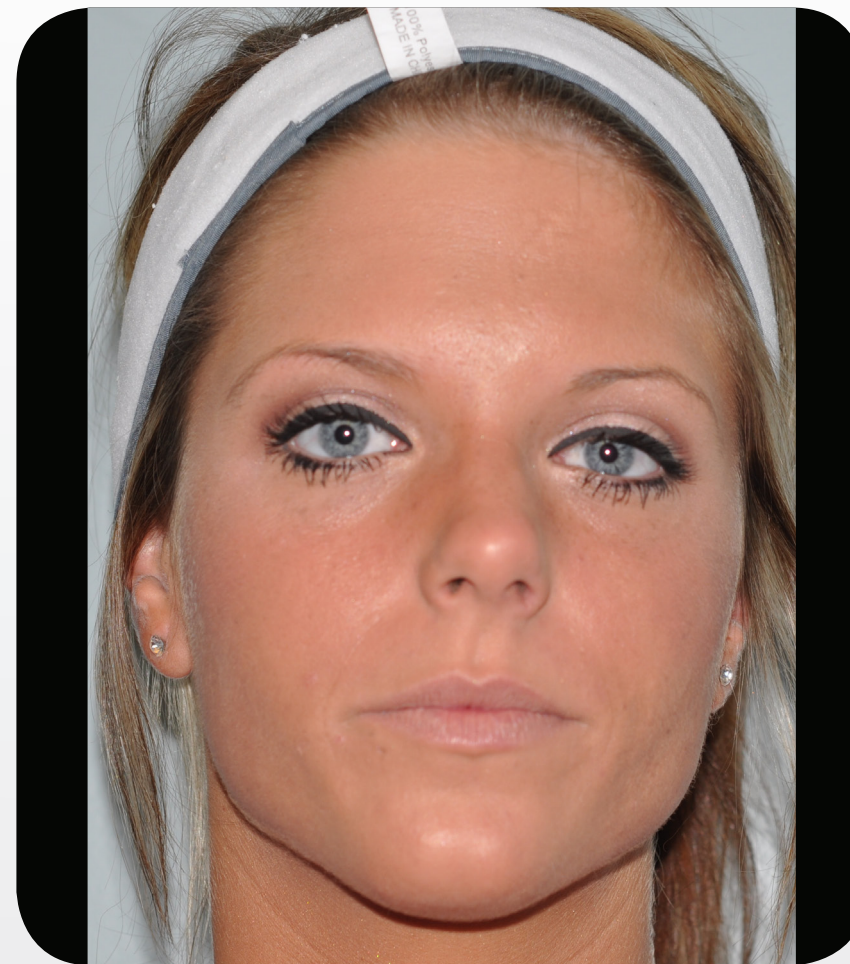Courtesy of Jill S. Waibel, MD

PB-1003880 Rev C

# Scar Revision The Berns Triplets; Chandra, Trae & Jordan



Baseline



After treatment

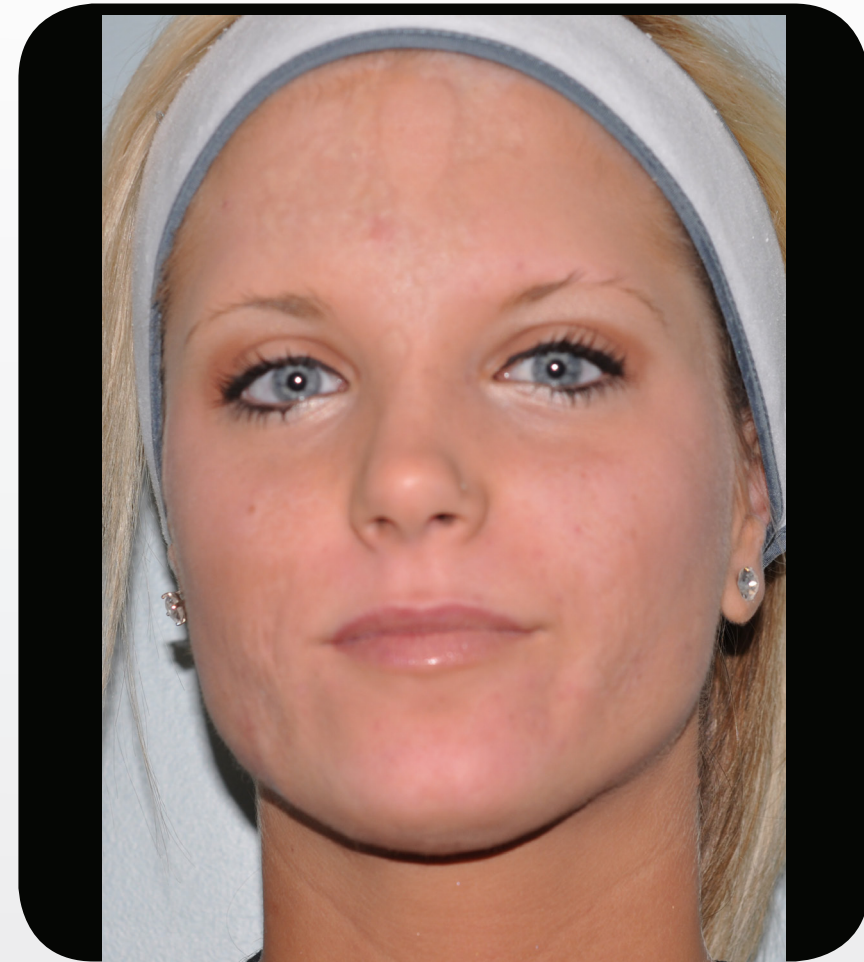Courtesy of Jill S. Waibel, MD

PB-1003880 Rev C

# Scar Revision The Berns Triplets; Chandra, Trae & Jordan



Baseline

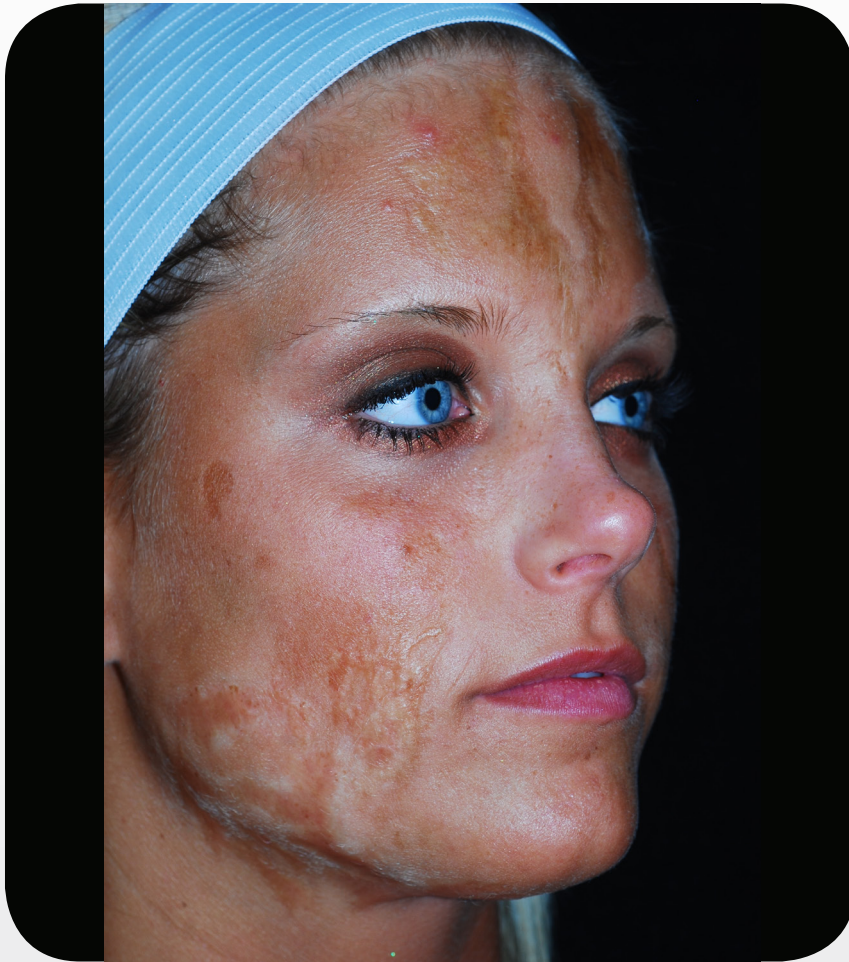

After treatment

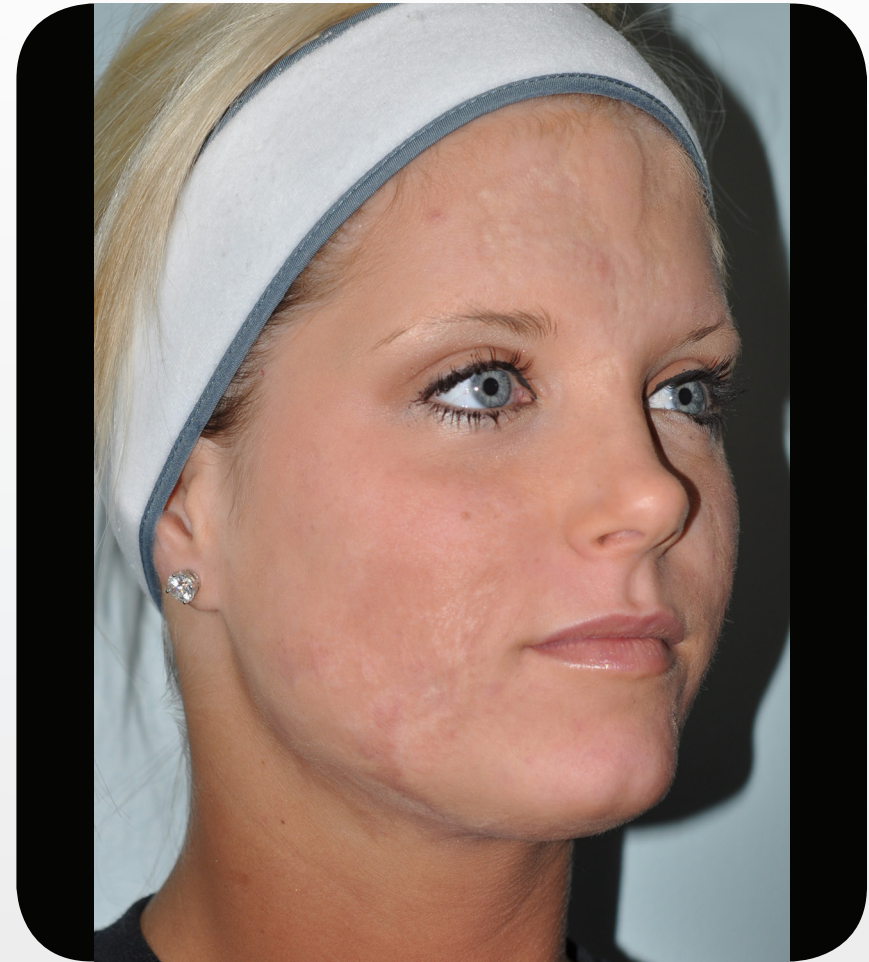Courtesy of Jill S. Waibel, MD

PB-1003880 Rev C

# Scar Revision The Berns Triplets; Chandra, Trae & Jordan



Baseline



After treatment

Courtesy of Jill S. Waibel, MD

PB-1003880 Rev C